



International Journal of PharmTech Research

CODEN (USA): IJPRIF, ISSN: 0974-4304, ISSN(Online): 2455-9563
Vol.13, No.03, pp 223-228, 2020

Characteristics of PSOAS Abscess in Patient with Tuberculosis spondylitis from 2016 to 2018 in Haji Adam Malik General Hospital Medan

John Tuahta P. Sinurat^{1*}, Pranajaya Dharma Kadar², Reza Mahruzza²

¹Resident of Orthopaedic and Traumatology, Faculty of Medicine Sumatera Utara University/Haji Adam Malik General Hospital, Medan, Indonesia

²Consultant of Orthopaedic and Traumatology, Faculty of Medicine Sumatera Utara University/Haji Adam Malik General Hospital, Medan, Indonesia

Abstract : Objective- Psoas abscess one of rare manifestation of tuberculosis spondylitis. 5% of cases will develop psoas abscess and can increase the number of morbidity and mortality if the diagnosis and treatment were late. **Material and Method-**This is a cross sectional study to determine characteristics of psoas abscess in patient with tuberculosis spondylitis. The data is taken from patient's medical record in Haji Adam Malik General Hospital from January 2016 to Desember 2018. The Population of this study is all the patients with tuberculosis spondylitis who come to Emergency Department or Outpatient Clinic. The collected data is tabulated and presented in the form of a frequency distribution diagram or table and analysed descriptively using total sampling. **Results-**The Subject for this study are 13 patients, within the proportion 5 patients are male (38.5%) and 8 patients are female (61.5%). The data show 5 patients have the ages < 18 years old (38.5%) and 8 patients have the ages > 18 years old (61.5%). All the patients get antituberculosis drugs as non operative treatment and 11 patients (84.6%) get an additional operative treatment for drainage the abscess. The site of psoas abscess in this study, 3 patients developed in thoracolumbal region (21.7%), 7 patients developed in lumbal region (53.8%) and 3 patients developed in lumbosacral region (21.7%). **Conclusion-** from this study we conclude that the incidence are happened in female more common than male, it usually affects young adult >18 years old and the common site of psoas abscess is lumbar region.

Keywords : Psoas abscess, Pott's Disease, tuberculosis spondylitis, lumbar abscess.

John Tuahta P. Sinurat *et al* /International Journal of PharmTech Research, 2020,13(3): 223-228.

DOI= <http://dx.doi.org/10.20902/IJPTR.2019.130313>

Introduction

Tuberculosis spondylitis is an extrapulmonary tuberculosis infection that usually affect the vertebrae and causes by *Mycobacterium tuberculosis*. Approximately 50% cases of Tuberculosis of the bone affect the vertebrae.

The United States reports that about 10% of all extrapulmonary TB affect bones and soft tissue. The disease often occurs men more common than females. Approximately 20% of cases, required for surgery and the most common site in thoracolumbar region.

About 5% of cases will develop psoas abscess and can increase the number of morbidity and mortality if the diagnosis and treatment were late.

The etiology of psoas abscess has change over the last few years. *Mycobacterium tuberculosis* causes psoas abscess through hematogenous spread or directly from lumbar osteomyelitis. Psoas abscess is a complication of spinal TB due to direct extension of other adjacent structures or even hematogenous from distant locations.

There is no data in Indonesia that record about the incidence and prevalence psoas abscess in tuberculosis spondylitis.

Method

This is a cross sectional study to determine characteristics of psoas abscess in patient with tuberculosis spondylitis. The data is taken from patient's medical record in Haji Adam Malik General Hospital from January 2016 to Desember 2018. The Population of this study is all the patients with tuberculosis spondylitis who come to Emergency Department or Outpatient Clinic.

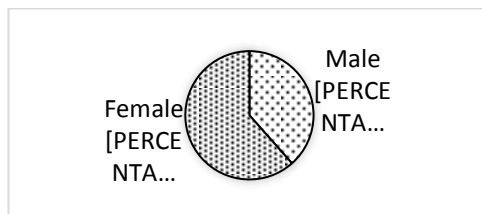
The inclusion criteria in this study is all the patient's medical record with tuberculosis spondylitis who develop psoas abscess that come to Haji Adam Malik General Hospital in Medan.

The collected data is tabulated and presented in the form of a frequency distribution diagram or table and analysed descriptively using total sampling.

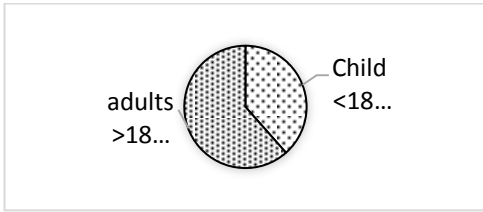
All statistical calculation are carried out using a computer-based statistical program. This study was approved by the Hospital Health Research Ethics Committee of the faculty of Medicine, University of North Sumatra / Haji Adam Malik.

Results

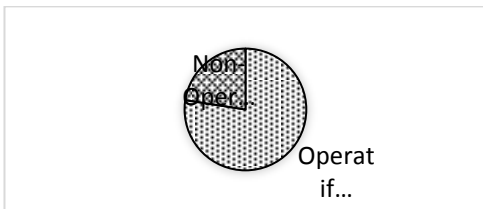
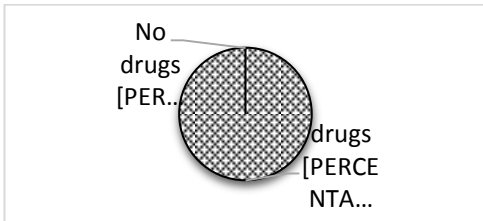
The subject of this study are 13 patients and the characteristics of the subject will be presented in the diagram.



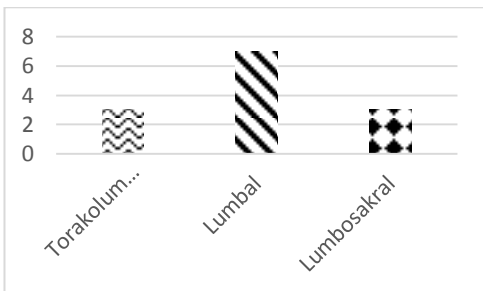
From this study, approximately 5 patients are male (38%) and 8 patients are female (62%).



From this study, approximately 5 patients are children <18 years old (38%) and 8 patients are young adults > 18 years old (62%).



From this study, all the patients have antituberculosis drugs therapy and 11 patients undergo surgical abscess drainage (84.6%).



The location of psoas abscess in this study are 3 patients develop in Thoracolumbal region (23.1%), 7 patients develop in lumbal region (53.8%) and 3 patients develop in lumbosacral region (23.1%).

Discussion

From this study, 5 patients are male (38%) and 8 patients are female (62%). The results show the cases occurs female more common than male.

Abdul *et al* has different result, his study has 6 subject, 4 patients are male and 2 patient are female. The other study from Pakistan also show different result, they has 15 patients, 6 patients are female and 9 patients are male.

From this study, 5 patients are children <18 years old (38%) and 8 patients are young adults > 18 years old (62%).

Hsieh et al report about 88 patients with psoas abscess have mean age 63.0 ± 15.6 . Garcia et al also report mean age 53 years old.

Psoas abscesses rarely occur in children, and diagnosis is difficult because of the varied clinical signs of the disease. Psoas abscesses are more common in younger people than older people; 83% of cases of primary psoas abscess are detected in people younger than 30 years, while 40% of cases with secondary psoas abscess are found in people older than 40 years. The average age of the cases found was 12.8 years.

All the patients get antituberculosis drug therapy. The regimen are isoniazid, rifampisin, pirazinamid and etambutol for 9 months. 11 patients undergo surgical abscess drainage.

Tabrizan et al report the treatment were divided into three groups, 9 patients (15%) who received antibiotic therapy only, of all patients only 1 patient who had an abscess <3.5 cm. Success rate is 78% (7 out of 9 patients). 48 patients (79%) had percutaneous drainage with a success rate of 40% (19 out of 40 patients) having an average abscess size of 7 cm. 7% (4 out of 61 patients) had an average abscess size of 4 cm performed exploratory and drainage operative measures, and all actions were successfully carried out. In the study patients with bacteremia and small abscesses (<3.5 cm) had good responses with antibiotics only. However, no specific relationship was found between abscess size and treatment success.

The location of psoas abscess in this study are 3 patients develop in Thoracolumbal region (23.1%), 7 patients develop in lumbar region (53.8%) and 3 patients develop in lumbosacral region (23.1%).

A study conducted by Dave in India from October 2003 to October 2011 of 29 psoas abscess patients. Of the total patients, 15 patients had abscesses in the L4-L5 vertebra, 12 abscess patients were found in the upper lumbar region, and 2 abscess patients were found in the dorsolumbar region.

Other studies also say that the lumbar vertebrae are often affected by abscesses. A study conducted by Li in China of 41 patients with thoracic and lumbar tuberculosis spondylitis. Lesions were found as high as T8 to the lowest part in S1. (1 case in T8-T9, 6 cases in T11-T12, 9 cases in T12-L1, 8 cases in L1-L2, 1 case in L1-L3, 6 cases in L2-L3, 5 cases in L3-L4, 4 cases in L4-L5, and 1 case found in L5-S1).

The most common site affect in Tuberculosis spondylitis are the thoracic and lumbar vertebrae, especially in the thoracolumbar region. An abscess that descends following gravity along the major psoas muscle in the thoracolumbar or lumbar region will form a psoas tuberculosis abscess.

Conclusion

from this study we conclude that the incidence are happened in female more common than male, it usually affects young adult >18 years old and the common site of psoas abscess is lumbar region.

References

1. Kusmiati T, Narendrani HP. Pott's Disease. *Jurnal Respirasi*. 2016;2(3):99-109.
2. Rajasekaran S, Soundararajan DCR, Shetty AP. Spinal Tuberculosis: Current Concepts. *Global Spine Journal*. 2018;8(4S):97S-107S.
3. World Health Organization. Global Tuberculosis Report 2018. Available from : https://www.who.int/tb/publications/global_report/en/ Diakses tanggal 24 juni 2019.
4. Vitriana. Spondilitis Tuberkulosa. Universitas Indonesia. 2002.
5. Hidalgo, JA. Pott Disease (Tuberculous [TB] Spondylitis). Available from : <http://emedicine.medscape.com/article/226141-overview#> Diakes tanggal 21 Mei 2019.
6. Karabella I, Meliou M. *Journal of Research and Practice on The Musculoskeletal System*. 2017;1(1):1-4.
7. Tarhan H, Cakmak O, Turk H, Can E, Un S, Zorlu F. Psoas abscess: evaluation of 15 cases and review of the literature. *J Urol Surg*. 2014; 1:32-35.
8. Santoso, KE, Liman, MN, Sudirman, T. Abses Psoas Tuberkulosis. *Medicinus*. 2016;5(2):42-7.

9. Cheong, JS, Eom, KS. Tuberculous Abscess of the Psoas Muscle in a Patient with Acute Lumbar Burst Fracture: A Missed Diagnosis. *Korean J Spine*. 2011; 8(4):288-291.
10. Kimizuka, Y, Ishii, M, Murakami, K, Ishioka, K, Yagi, K. A case of skeletal tuberculosis and psoas abscess: disease activity evaluated using 18 F-fluorodeoxyglucose positron emission tomography-computed tomography. *BMC Medical Imaging*. 2013; 13:37.
11. Latif, A. Bilateral Psoas Abscess and Extensive Soft Tissue Involvement Due to Late Presentation of Pott's Disease of the Spine. *Indian J Surg*. 2011; 73(2):161-162.
12. Dave BR, Kurupati RB, Shah D, Degulamadi D, Borgohain N, Krishnan A. Outcome of Percutaneous Continuous Drainage of Psoas Abscess: A Clinically Guided Technique. *Indian Journal of Orthopaedics*. 2014;48(1):67-73.
13. Sharma, K, Suhani, Ali, S, Aggarwal, L, Thomas, S. Bilateral extensive tubercular iliopsoas abscess: An Uncummon Manifestation of Pott's Spine. *Annals of TropMed & Public Health*. 2015;8(1):10-12.
14. Rahyussalim. Spondilitis Tuberkulosis: Diagnosis, Penatalaksanaan, dan Rehabilitasi. Jakarta: Media Aesculapius;2018. p.39-63.
15. Mallick IH, Thoufeeq MH, Rajendran TP. Review Iliopsoas Abscesses. *Postgrad Med J*. 2004;80(946):459-462.
<http://dx.doi.org/10.1136/pgmj.2003.017665>
16. Lai Z, Shi S, Fei J, Han G, Hu S. A Comparative Study to Evaluate The Feasibility of Preoperative Percutaneous Catheter Drainage for The Treatment of Lumbar Spinal Tuberculosis with Psoas Abscess. *Journal of Orthopaedic Surger and Research*. 2018;13(290):1-8.
17. Uddin MM, Sultana N, Rehan R, Khns AA. Pott's Disease with Psoas Abscess in a D iabetic Patient : A Conservative Approach. *CMOSHM CJ*.2014;13(2):67-69.
18. Khorgade RR, Bhise PR, Deshmukh MM. Psoas Abscess due to Mycobacterium Tuberculosis: A Case Report. *Int J Res Med Sci*. 2017;5(7)L3251-53.
19. Zuwanda, Janitra R. Diagnosis dan Penatalaksanaan Spondilitis Tuberkulosis.CDK. 2013;40(9):661-673.
20. Shields, D, Robinson, P, Crowley,TP. Illiopsoas Abscess – A review and update on the literature. *International Journal of Surgery*. 2012;10:466-469.
21. LAI, Yi-Chun, et al. An update on psoas muscle abscess: an 8-year experience and review of literature. *International Journal of Gerontology*, 2011, 5.2: 75-79.
22. Dietrich, Agustin; Vaccarezza, Hernán; Vaccaro, Carlos A. Iiopsoas abscess: presentation, management, and outcomes. *Surgical Laparoscopy Endoscopy & Percutaneous Techniques*, 2013, 23.1: 45-48.
23. Jackson R, Stephens L, Kelly AP. Cold subcutaneous abscesses. *Journal of the National Medical Association*. 82(10):733-736.
24. KIM, Youn Jeong, et al. Etiology and outcome of iliopsoas muscle abscess in Korea; changes over a decade. *International Journal of Surgery*, 2013, 11.10: 1056-1059.
25. V. Navarro Lopez, J.M. Ramos, V. Meseguer, J.L. Perez Arellano, R. Serrano, M.A. Garcia Ordonez, et al. Microbiology and outcome of iliopsoas abscess in 124 patients *Medicine*, 88 (2) (2009), pp. 120-130
26. Sanal, HT, Kocaoglu, M, Sehirlioglu, A, Bulakbasi. A Rare Cause of Flank Mass: Psoas Abscess due to Exxtensive Primary Thoracolumbar Tuberculous Spondylodiskitis. *American Journal of Neuroradiology*.2016;27(8):1735-1737.
27. Ingole K, Pawar S, thak S, Sharma A. Psoas Abscess Secondary to Pott's Spine: A Case Report. *IOSR Journal of Dental and Medical Science*. 2016;15(5):118-121.
28. Moesbar N. Infeksi Tuberkulosa pada Tulang Belakang. *Majalah Kedokteran Nusantara*. 2006;39(3):279-289.
29. Wibowo BF, Manjas N, Sahputra RE, Erkadius. Hubungan Pemeriksaan LED dan CRP pada Penegakkan Diagnosis Spondilitis TB di RSUP dr. M. Djamil Padang Tahun 2014-2016. *Majalah Kedokteran Andalas*. 2018;41(2):69-77.
30. Altintas N, Tuerkeli S, Yilmaz Y, Sariaydin M, Yasayancan N. A Rare Case of Tuberculosis Psoas Abscess. *Eur J Gen*. 2012;9(2):159-161.
31. Takada, Toshihiko, et al. Limitations of using imaging diagnosis for psoas abscess in its early stage. *Internal Medicine*, 2015, 54.20: 2589-2593

32. Basu, Sandip; Mahajan, Abhishek. Psoas muscle metastasis from cervical carcinoma: Correlation and comparison of diagnostic features on FDG-PET/CT and diffusion-weighted MRI. *World journal of radiology*, 2014, 6.4: 125.
33. Gehlot, Prateek S., et al. Pott's spine: retrospective analysis of MRI scans of 70 cases. *Journal of clinical and diagnostic research: JCDR*, 2012, 6.9: 1534.
34. Tabriian, P, Nguyen, SQ, Greenstein, A, Rajhbeharrysingh, U, Divino, CM. Management and Treatment of Iliopsoas Abscess. *Arch Surg*. 2009;144(10):946-949.
35. Camillo, FX. Chapter 42: Infections and Tumors of the Spine. *Campbell's Operative Orthopaedics*. Ed 13th. Elsevier. 2017. p1824-1856.
36. Van den Berge, M, de Marie, S, Kuipers, T, Jansz, AR, Bravenboer, B. Psoas abscess: report of a series and review of the literature. *The Netherlands Journal of Medicine*. 2005;63(10):413-416.
37. Alvi, AR, Rehman, ZU, Nabi, ZU. Pyogenic Psoas Abscess: Case Series and Literature Review. *Tropical Doctor*. 2010;40:56-58.
38. Wong OF, Ho PL, Lam SK. Retrospective Review of Clinical Presentations, Microbiology, and Outcomes of Patients with Psoas Abscess. *Hong Kong Med J*. 2013;19:416-423.
39. Li J, Li XL, Zhou XG, Zhou J, Dong J. Surgical Treatment for Spinal Tuberculosis with Bilateral Paraspinal Abscess or Bilateral Psoas Abscess One- Stage Surgery. *J Spinal Disord Tech*. 2014;27(8):309-314.
40. Tabrizian P, Nguyen SZ, Greenstein A, Rajhbeharrysingh U, Divino CM. Management and Treatment of Iliopsoas Abscess. *Ach Surg*. 2009;144(10):946-949.
41. Yacoub WN, Sohn HJ, Chan S, Petrosyan M, Vermaire HM, Kelso RL, Towfigh S, Mason RJ. Psoas Abscess Rarely Requires Surgical Intervention. *The American Journal of Surgery*. 2008; 196(2):223-227.
42. Rahyussalim, Kurniawati T, Setiawaty V. Preservasi Kolum Posterior dengan Menggunakan Teknik Debridemnt Invasi Minimal pada Penderita Spondilitis Tuberkulosis Torakal Umur 2 Tahun. *Media Lubangkes*. 2015; 25(2):9-18.
43. Dharmajaya R. Tuberculous Spondylitis in Haji Adam Malik Hospital, Medan. *IOP Conf. Series: Earth and Environment Science*. 2018;125:1-5.
44. Nigam A, Prakash A, Pathak P, Abbey P. Bilateral psoas abscess during pregnancy presenting as an acute abdomen: atypical presentation. *BMJ Case Rep* 2013. p. 1-3. doi:10.1136/bcr-2013-200860.
45. Ijaz M, Sakam S, Ashraf U, Marquez JG. Unusual Presentation of Recurrent Pyogenic Bilateral Psoas Abscess Causing Bilateral Pulmonary Embolism by Iliac Vein Compression. *Am J Case Rep*. 2015; 16: 606-610.
46. Baier PK, Arampatzis G, Imdahl A, Hopt UT. The Iliopsoas Abscess : Aetiology, Therapy, and Outcomes. *Langenbecks Arch Surg*. 2006;391:411-417.
47. Hsieh MS, Huang SC, Loh EW, Tsai CA, Hung YY, Tsan YT, et al. Features and treatment modality of iliopsoas abscess and its outcome: A 6-year hospital-based study. *BMC Infect Dis*. 2013.
48. Garcia MP, Laguna EP, Lopez-Cano GM, Castaneda PA, Gil NM. Pyogenic and Tuberculous Abscesses of The Psoas Muscle. *Revista Clinica Espanola*. 2011;211(11):572-578.
49. Sudirman T. Abses Psoas Tuberkulosis. *Medicinus*. 2018.
50. Karli A, Belet N, Danaci M, Avcu G, Paksu Ş, Köken Ö, et al. Iliopsoas abscess in children: Report on five patients with a literature review. *Turk J Pediatr*. 2014.
51. Wei HL, Wang L, Du XG, Wu Y, Li H, Cai Y, et al. Renal tuberculosis and iliopsoas abscess: Two case reports. *Exp Ther Med*. 2014.
52. Kramer L, Geib V, Evison J, Altpeter E, Basedow J, Brügger J. Tuberculous sacroiliitis with secondary psoas abscess in an older patient: A case report. *J Med Case Rep*. 2018.
53. De Nardo P, Corpolongo A, Conte A, Gentilotti E, Narciso P. Total hip replacement infected with *Mycobacterium tuberculosis* complicated by Addison disease and psoas muscle abscess: A case report. *J Med Case Rep*. 2012.
54. Akturk H, Torun SH, Aliskan BC, et al. A Late Diagnosis of Pott's Disease in an Adolescent with Psoas Abscess. *Marmara Medical Journal*. 2015;28:165-168.
55. Muckley T, Schutz T, Kirschner M, Potulski M, Hofmann G, Bühren V. Psoas Abscess : The Spine as a Primary Source of Infection. *Lippincott Williams & Wilkins Inc*. 2003;28(6):E106-E113.
