

Impact of Different Wave Lengths of Low Level Laser Therapy on Bone Repair: Histological Study in Rats

Ahmed El Prince Mohamed¹, Yousry Mahmoud Mostafa², Nashwa Taher Abdel Aziz³ and Engy Mohamed El Nahas⁴

¹M Sc in Physical Therapy for musculoskeletal disorders and its surgery, Faculty of Physical Therapy, Cairo University, Egypt

²Professor in Department of Medical Application of Laser- NILES - Cairo University, Egypt

³ Professor of Rehabilitation and Physical Medicine-Faculty of Medicine - Cairo University, Egypt

⁴Lecturer of Physical Therapy for Obstetrics and Gynecology- Faculty of Physical Therapy- Cairo University, Egypt

Abstract: This study was conducted to determine the effect of different wave lengths of low level laser therapy (LLLT) on bone repair in rats. Seventy two female rats were assigned randomly into three groups, **group (A)** consisted of twenty four rats whose bone fracture didn't receive laser therapy, **group (B)** consisted of twenty four rats whose bone fracture received He-Ne laser (632.8 nm) and **group (C)** consisted of twenty four rats whose bone fracture received Ga-As laser (905 nm). Each group was subdivided into three subgroups according to their sacrificing day on 15th, 30th and 45th post-operative days. Assessment of bone fracture healing was done through radiological analysis and histopathological analysis. The results of this study revealed that group (C) showed more complete bone regeneration on 15th and 30th post-operative days when compared with groups (A&B) according to the radiological findings. On 15th and 30th postoperative days, there was no statistically significant difference between groups (A&B) ($p > 0.05$) in newly formed blood vessels, fibroblasts, osteoid and bone formation scores. While, there was a significant difference between groups (A&C) and (B&C) in favor of group (C) (p value < 0.05). So, it could be concluded that infrared laser showed a biostimulating effect on bone repair by stimulating the modulation of the initial inflammatory response and anticipating the resolution to normal condition at the earlier periods. However, there were no differences between groups on 45th post-operative day.

Key words: low level laser therapy- bone repair.

Introduction

Bone remodeling is characterized as a cyclic and lengthy process. It is currently accepted that not only this dynamics is triggered by a biological process, but also biochemical, electrical, and mechanical stimuli are key factors for the maintenance of bone tissue. The hypothesis that low-level laser therapy (LLLT) may favor bone repair has been suggested¹.

The need for repairing bone defects has attracted the interest of researchers of several health fields. Currently, bone increment stimulus has been achieved with the application of chemical stimuli, biomaterials,

bone morphogenetic proteins (BMPs) as well as the use of physical stimuli, such as ultrasound, electromagnetic fields and more recently low-level laser therapy (LLLT)¹.

The healing of bone differs from that observed on soft tissue because of their different morphological characteristics. Usually, the healing process of bone is slower than that of soft tissue. The natural course of bone healing includes consecutive phases and differs according to the type and intensity of the trauma and also the extension of the damage to the bone².

Low energy laser irradiation has positive effects on bone fracture healing. The mechanisms by which low-energy laser irradiation affect the bone healing still not clear³. He-Ne low-level energy treatment accelerates the deposition of bone matrix and increases vascularization after seven days of irradiation⁴. Direct irradiation of the whole injury with He-Ne laser on days five, six post-injury altered the osteoblast and osteoclast cell population. Studies on animals were performed on the effect of low-level laser of fracture healing indicated that, the laser enhanced healing⁵.

Therapeutic strategies to promote bone repair represent a major challenge to many health professionals. In order to reduce the functional incapacity and the high socioeconomic costs associated with the bone fractures, several interventions have been investigated on bone healing process, and these include the use of low-level laser therapy (LLLT)⁶.

The LLLT involves the application of monochromatic and coherent light with low energy density that promotes non-thermal photochemistry effects on cellular level. It has been described that LLLT may accelerate the healing of bone defects in vivo and in vitro investigations. It was showed that osteoblastic activity increased, vascularization, organization of collagen fibers, and mitochondrial and intracellular adenosine triphosphate level changes⁶.

A significant body of evidence has now accumulated demonstrating that low-level laser therapy (LLLT) has a positive effect on bone tissue metabolism and on fracture consolidation. When a laser is applied to tissue, the light is absorbed by photoreceptors located in the cells. Once absorbed, the light can modulate cell biochemical reactions and stimulate mitochondrial respiration, with the production of molecular oxygen and ATP synthesis. These effects are known to increase the synthesis of DNA, RNA, and cell-cycle regulatory proteins, therefore promoting cell proliferation⁷.

Materials and Methods

This study was conducted to determine the effect of low level laser therapy (LLLT) on the repair of bone fracture of the tibia of rats and to compare between the non-irradiated bone repair and the irradiated bone repair (using two types of wave lengths).

• Animals:

The sample consisted of 72 young adult female wistar rats, weighing between (200-250) g and their age ranged between 10-15 weeks. The animals were kept in individual cages in environmentally controlled temperature and light conditions. They were fed solid food and water at the Animal Experimentation Laboratory of the National Institute of Laser Enhanced Science, Cairo University. All animal handling and procedures were strictly conducted according to the regulations for the care and use of Laboratory Animals.

In this study, rats were used as the experimental model, because of the positive bone tissue responses in this mammal, which resemble those found in humans, and also because of the ease of acquiring and handling these animals⁸.

The animals were divided into three groups equal in number: **group (A) (control group)** consisted of 24 healthy rats whose bone fracture didn't receive laser therapy, **group (B) (He Ne laser group)** consisted of 24 rats whose bone fracture received laser therapy in the red spectrum with wave length 632.8 nm and **group (C) (Ga As laser group)** consisted of 24 healthy rats whose bone fracture received laser therapy in the infrared spectrum with wave length 905nm.

Each group (A), (B) and (C) was subdivided into three subgroups (1, 2 and 3) according to their sacrificing day (every fifteen days) on 15th, 30th and 45th post-operative days. Each subgroup consisted of eight rats.

- **Surgical procedures:**

- **Anesthesia:**

Ketamine 50 mg per kg of body weight, Xylazine 5 mg per kg of body weight and Thiopental sodium 50 mg per kg of body weight were used to anesthetize the rats.

- **Surgery:**

The right leg of the animal was shaved and the tibia was exposed, then a veterinarian made a complete fracture in the middle shaft of the of the tibia using a carbon disc attached to a mini drill (*Fig.1*). A spinal needle 25 gauge was used as intra-medullary pin which was introduced through the fracture proximal part then through the head of the tibia using manual mini drill (*Fig.2*). After penetrating the tibial head, the spinal needle was withdrawn till the needle distal part get through the distal tibial bone. The mini drill revolved the pin into the distal part of tibia till fixation was completed, then suturing of the skin was done. Post-operative antibiotic was given to each rat in all groups every day for 5 successive days to avoid post-operative infection.

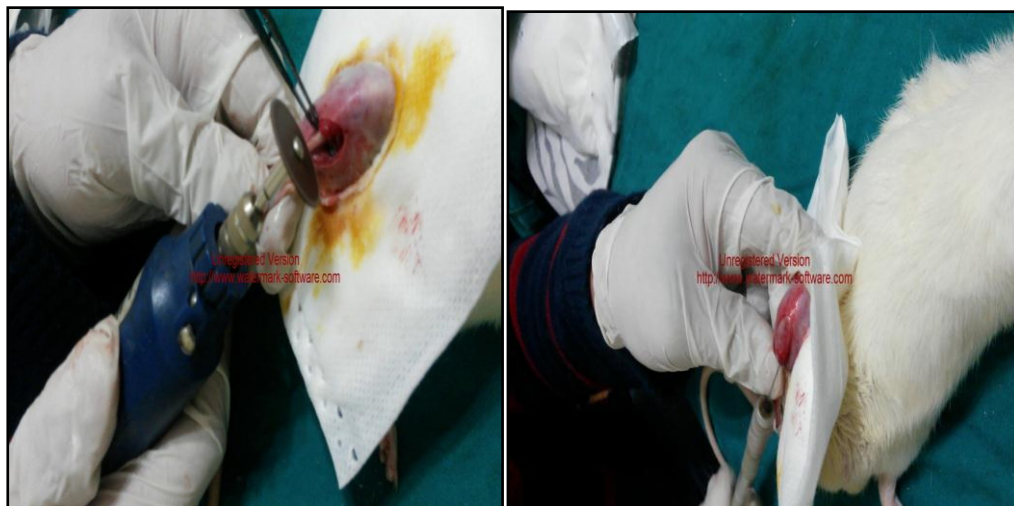

Fig.(10): A carbon disc attached to mini drill. Fig.(11): Introducing the intra-medullary pin.

- **Radiological examination:**

Dental x-ray machine (Castellini) (model: victory x50) was used to assess the healing of the bone of the rats. Technical Specification: voltage: 60 KV, electric charge: 30mA, frequency: 50Hz, kodak film and D speed.

- **Histopathological analysis:**

Eight animals per group were sacrificed by over dose of general anesthesia at each of the predetermined evaluation periods on 15th, 30th and 45th postoperative days. This was done by doubling dose of anesthesia. Their radiated tibias and control tibias were immediately defleshed, dissected and fixed. Bone sample of mid shaft of the tibia was taken and prepared for histological examination. The specimens were fixed by immersion in 4% neutral buffered formaldehyde, then decalcified in Decolc nr CT 1135 (salt acid 14 % and polyvinyl pyrrolidon 7%), dehydrated in a graded series of ethanol, placed in xylene, and embedded in paraffin.

They were cut in transverse and vertical sections about 5µm thick and then stained with hematoxylin-eosin (H&E) as a general stain, Masson's trichrome to differentiate collagen and bone from smooth muscle in tissues, and saffranin von kossa stain to identify the calcified bone tissue and to monitor cartilage formation.

The sections were examined under a microscope (Nikon, Eclipse E 600, Tokyo, Japan) connected to an image analyzer (Soft Imaging System GmbH, Heidelberg, Germany). Using (x20) and (x40) magnification objective and fixed grid, the following parameters were measured: 1) number of newly formed vessels, 2) fibroblasts, 3) osteoid (bone matrix), and 4) bone. The results were evaluated on a graded scale. The scoring was based on the degree of healing as: (0) absent, (1) mild, (2) moderate, and (3) pronounced, according to the criteria stipulated in (*Table 1*).

Table (1): Criteria for scoring histological sections.

Score	Parameter	Criteria
0	<ul style="list-style-type: none"> • Newly formed blood vessels. • Number of fibroblasts. • Osteoid (bone matrix). • Bone. 	<ul style="list-style-type: none"> • None • None to very minimal. • None. • None.
1	<ul style="list-style-type: none"> • Newly formed blood vessels. • Number of fibroblasts. • Osteoid (bone matrix). • Bone. 	<ul style="list-style-type: none"> • Few blood vessels. • Few fibroblasts. • Evidence of matrix osteoid. • Evidence of bone formation.
2	<ul style="list-style-type: none"> • Newly formed blood vessels. • Number of fibroblasts. • Osteoid (bone matrix). • Bone. 	<ul style="list-style-type: none"> • Moderate blood vessels number. • Predominantly fibroblasts. • Moderate bone matrix deposition. • Moderate bone cells.
3	<ul style="list-style-type: none"> • Newly formed blood vessels. • Number of fibroblasts. • Osteoid (bone matrix). • Bone. 	<ul style="list-style-type: none"> • Extensive blood vessels. • Extensive number of fibroblasts. • Dense highly organized bone matrix. • Extensive bone cells.

- **Laser devices:**

1. **Red laser (He-Ne laser):**

Laser therapy (Biorem), designed by ASA medical laser (German), red laser helium neon, wave length 632.8nm. Clearly visible LCD display with digital display of all parameters. Technical Specification: wave length: 632.8nm, pulse frequency: 50 Hz, power: 300W, voltage: 220V.

2. **Infrared laser (Ga-As laser):**

Laser Therapy (LIS 1050), designed by Business Line (EME), pulsed infrared gallium arsenide (Ga-As), wave length 905 nm. Clearly visible LCD display with digital display of all parameters. Technical Specifications: diode laser wave length: 905nm, classification: IIIB, pulse frequency: 200-10000Hz, peak power: 25W, voltage: 230 V, 50-60 Hz, $\pm 10\%$, dimensions of the unit (width x height x depth): 39x14x30cm and unit body weight: 3.25Kg.

- **Treatment procedures:**

Groups (B) and (C) were submitted to seven sessions of laser radiation. The first dose was given immediately after surgery, the second application occurred 24 hours after surgery, and the others occurred every 48 hours. The irradiations were applied directly on the fracture site. A specially designed tube was used to keep the rat inside it without movement during the exposure to laser.

In group (B), a laser in the red spectrum (He Ne laser) was used with wave length 632.8nm, power output 25mW, spot size 0.19 cm² and incident power density around 132 mW/cm². The exposure time per session was 3 minutes, giving an energy density of 23.5 J/cm².

In group (C), a laser in the infrared spectrum (Ga As laser) was used with wave length 905nm, power output 77mW, spot size 0.13 cm² and incident power density around 590 mW/cm². The exposure time per session was 40 seconds, giving an energy density of 23.5 J/cm².

All animals were treated in the same way. The animals were positioned on a table in ventral decubitus. The laser was used on their affected limbs, directly on the injury, at a 90° angle.

- **Statistical analysis:**

Data are expressed as median (range). Comparison between different variables in the three studied groups was performed using Kruskal Wallis test followed by Mann Whitney U test as a post hoc test if significant results were recorded. Statistical Package for Social Sciences (SPSS) computer program (version 19 windows) was used for data analysis. P value less than or equal to 0.05 was considered significant and < 0.01 was considered highly significant.

Results

- **Radiological findings:**

On 15th postoperative day: There was an evidence of healing fracture inform of minimal callus formation with decreased fracture gaping in all groups (A, B&C) in favor of group (C). **On 30th postoperative day:** There was incomplete healing showing callus formation filling the fracture gaping in groups (A&B) and nearly complete healing in group (C). **On 45th postoperative day:** Complete healing was observed in all groups (A, B&C) (*Fig.3*).

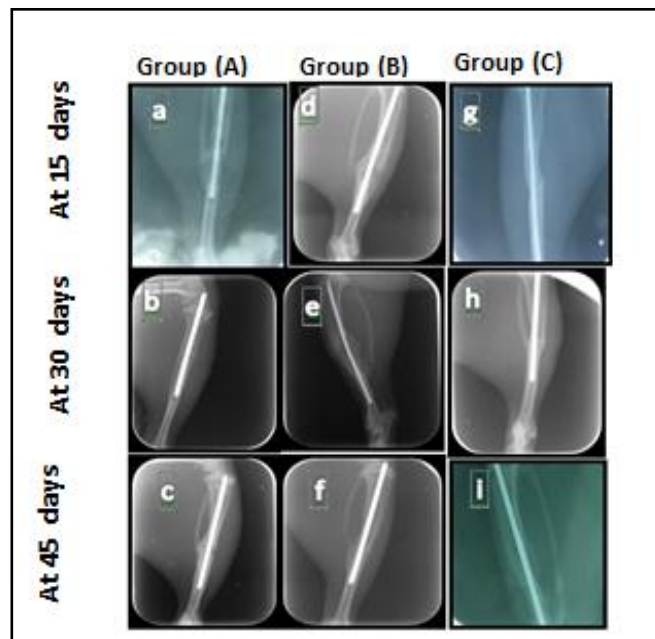


Fig. (3): X-ray of the tibia on 15th, 30th and 45th postoperative days for group (A) (a, b &c), for group (B) (d, e & f) and for group (C) (g, h & i).

- **Histopathological findings:**

- **Group (A) (control group):**

On 15th postoperative day, light micrograph of the bone defect of group (A) showed tissue disorganization, newly formed blood vessels, poor fibrous ingrowth and no bone ingrowth as shown in (*Fig. 4a*), necrotic tissue and degenerating cells as shown in (*Fig. 4b*). **On 30th postoperative day,** Light micrograph of the bone defect of group (A) showed osteoid formation with moderate bone ingrowth as shown in (*Fig. 4c*), abundant fibrous tissue formation and only few blood vessels as shown in (*Fig. 4d*). **On 45th postoperative**

day, light micrograph of the bone defect of group (A) showed bone tissue filling the defect as shown in (Fig. 4e), abundant bone ingrowth as shown in (Fig. 4f).

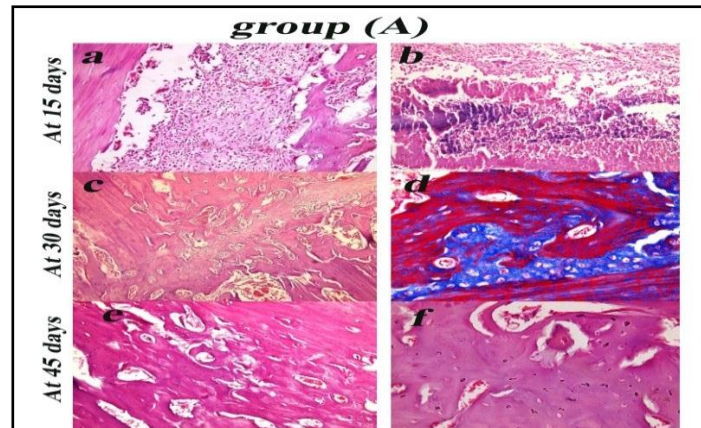


Fig.(4): Bone defect of group (A) on 15th postoperative day (a&b), on 30th postoperative day (c&d) and on 45th postoperative day (e&f).

➤ **Group (B) (He-Ne laser):**

On 15th postoperative day, light micrograph of the bone defect of group (B) showed the connective tissue filling the bone defect as shown in (Fig. 5a), many newly formed blood vessels and fibroblasts as shown in (Fig. 5b). On 30th postoperative day, light micrograph of the bone defect of group (B) showed newly formed bone tissue filling the defect with the presence of numerous capillaries as shown in (Fig.5c), partial filling of the bone defect as shown in (Fig.5d). On 45th postoperative day, light micrograph of the bone defect of group (B) showed filling of the bone defect with bone tissue as shown in (Fig. 5e&f).

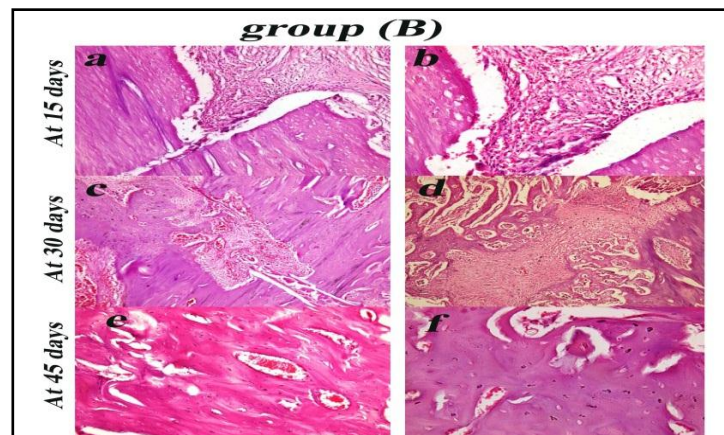


Fig.(5): Bone defect of group (B) on 15th postoperative day (a&b), on 30th postoperative (c&d) and on 45th postoperative (e&f).

➤ **Group (C) (Ga-As laser):**

On 15th postoperative day, light micrograph of the bone defect of group (C) showed more increase of newly blood vessels and fibroblast as shown in (Fig. 6a &b). On 30th postoperative day, Light micrograph of the bone defect of group (C) showed more filling of the bone defect with osteoid and newly formed bone tissue as shown in (Fig. 6c), more filling of the bone defect with osteoid and newly formed bone tissue and presence of blood vessels as shown in (Fig. 6d). On 45th postoperative, Light micrograph of the bone defect of group (C) showed complete filling of the bone defect with osteoid and newly formed bone tissue as shown in (Fig. 6e&f).

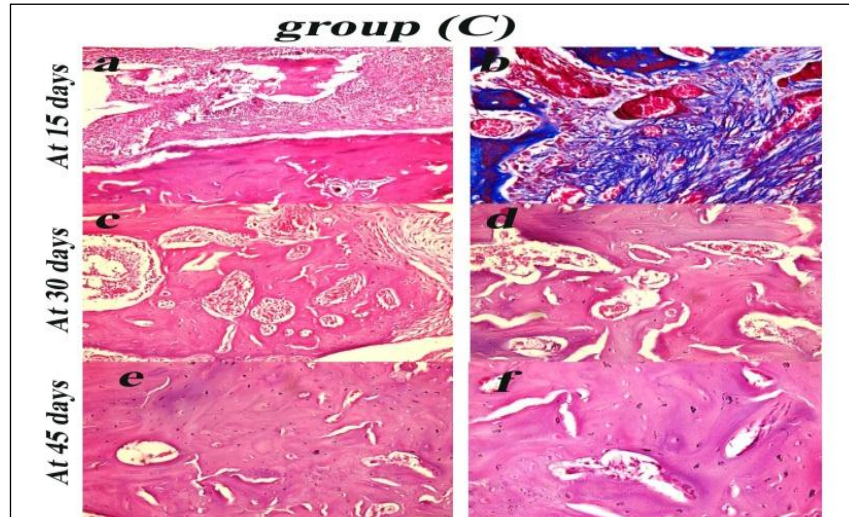


Fig.(6): Bone defect of group (C) on 15th postoperative day (a&b), on 30th postoperative (c&d) and on 45th postoperative (e&f).

➤ **Histopathological statistical analysis:**

a) **Newly formed blood vessels scores:**

Table (2), represents the comparison between the median for the newly formed blood vessels scores on 15th, 30th and 45th postoperative days for groups (A, B& C).

Table (2): Comparison between the median for newly formed blood vessels scores on 15th, 30th and 45th postoperative days for groups (A, B& C).

Newly formed blood vessels scores	Group (A)		Group (B)		Group (C)	
	Median	Range	Median	Range	Median	Range
On 15 th post-operative day	1.5	2.0	1.5	1.0	2.5	2.0
On 30 th post-operative day	2.0	1.0	2.0	2.0	3.0	1.0
On 45 th post-operative day	3.0	1.0	3.0	1.0	3.0	1.0

Table (3), represents the difference between groups (A, B and C) in the newly formed blood vessels scores on 15th, 30th and 45th post-operative days by the Kruskal- Wallis test (non parametric ANOVA).

Table (3): The difference between groups (A, B& C) in the newly formed blood vessels scores on 15th, 30th and 45th post-operative days.

Time	χ^2 value	P-value	Sig.
On 15 th post-operative day	7.07	0.02	S
On 30 th post-operative day	7.27	0.02	S
On 45 th post-operative day	2.19	0.33	NS

*Sig.: significance * χ^2 : Chi-square *S: significant *NS: no significant

Table (4), reveals the differences between groups (A, B and C) in the newly formed blood vessels scores on 15th and at 30th postoperative days using Mann-Whitney test.

Table (4): Mann-Whitney test for the newly formed blood vessels scores on 15th & 30th post-operative days.

Comparison	P-value	
	On 15 th post-operative day	On 30 th post-operative day
Group (A) vs. Group (B)	1.0 (NS)	0.95 (NS)
Group (A) vs. Group (C)	0.02 (S)	0.01(S)
Group (B) vs. Group (C)	0.02 (S)	0.03 (S)

b) Number of fibroblast scores:

Table (5), represents the comparison between the median for the number of fibroblast scores on 15th, 30th and 45th postoperative days for groups (A, B &C).

Table (5): Comparison between the median for number of fibroblast scores on 15th, 30th and 45th post-operative days for groups (A, B &C).

Fibroblasts scores	Group (A)		Group (B)		Group (C)	
	Median	Range	Median	Range	Median	Range
On 15 th post-operative day	1.0	1.0	1.0	1.0	1.0	1.0
On 30 th post-operative day	2.0	2.0	2.0	2.0	3.0	1.0
On 45 th post-operative day	3.0	1.0	3.0	1.0	3.0	1.0

Table (6), represents the difference between groups (A, B& C) in the Number of fibroblast scores on 15th, 30th and 45th post-operative days by the Kruskal- Wallis test (non parametric ANOVA).

Table (6): The difference between groups (A, B &C) in fibroblasts scores on 15th, 30th and 45th post-operative days.

Time	χ^2 value	P-value	Sig.
On 15 th post-operative day	6.7	0.03	S
On 30 th post-operative day	7.27	0.02	S
On 45 th post-operative day	0.48	0.78	NS

Table (7), reveals the differences between groups (A, B and C) in the number of fibroblast scores on 15th and 30th post-operative days using Mann-Whitney test.

Table (7): Mann-Whitney test for the number of fibroblast scores on 15th & 30th post-operative days.

Comparison	P-value	
	On 15 th post-operative day	On 30 th post-operative day
Group (A) vs. Group (B)	0.53 (NS)	0.95 (NS)
Group (A) vs. Group (C)	0.03 (S)	0.03 (S)
Group (B) vs. Group (C)	0.04 (S)	0.01 (S)

c) Osteiod formation scores:

Table (8), represents the comparison between the median for the osteiod formation scores on 15th, 30th and 45th postoperative days for groups (A, B &C).

Table (8): Comparison between the median for osteiod formation scores on 15th, 30th and 45th postoperative days for groups (A, B& C).

Osteiod scores	Group (A)		Group (B)		Group (C)	
	Median	Range	Median	Range	Median	Range
On 15 th post-operative day	1.0	1.0	1.0	1.0	2.0	2.0
On 30 th post-operative day	2.0	1.0	2.0	2.0	2.5	1.0
On 45 th post-operative day	3.0	1.0	3.0	1.0	3.0	1.0

Table (9), represents the difference between groups (A, B& C) in the osteiod formation scores on 15th, 30th and 45th post-operative days by Kruskal- Wallis test (non parametric ANOVA).

Table (9): The difference between groups (A, B & C) in osteiod formation scores on 15th, 30th and 45th post-operative days.

Time	χ^2 value	P-value	Sig.
On 15 th post-operative day	9.27	0.01	S
On 30 th post-operative day	7.46	0.02	S
On 45 th post-operative day	2.19	0.33	NS

*Sig.: significance * χ^2 : Chi-square *S: significant *NS: non significant

Table (10), reveals the differences between groups (A, B and C) in the osteoid formation scores on 15th and 30th postoperative days using Mann-Whitney test.

Table (10): Mann-Whitney test for the osteoid formation scores on 15th & 30th post-operative days.

Comparison	P-value	
	On 15 th post-operative day	On 30 th post-operative day
Group (A) vs. Group (B)	1.0 (NS)	0.79 (NS)
Group (A) vs. Group (C)	0.01 (S)	0.01 (S)
Group (B) vs. Group (C)	0.01 (S)	0.03 (S)

d) Bone formation scores:

Table (11), represents comparison between the median for bone formation scores on 15th, 30th and 45th post-operative for groups (A, B& C).

Table (11): Comparison between the median for bone formation scores on 15th, 30th and 45th post-operative days of groups (A, B& C).

Bone formation scores	Group (A)		Group (B)		Group (C)	
	Median	Range	Median	Range	Median	Range
On 15 th post-operative day	0.0	1.0	0.5	1.0	1.0	2.0
On 30 th post-operative day	1.5	1.0	2.0	1.0	3.0	1.0
On 45 th post-operative day	3.0	1.0	3.0	1.0	3.0	1.0

Table (12), represents the difference between groups (A, B &C) in the bone formation scores on 15th, 30th and 45th post-operative days by Kruskal- Wallis test (non parametric ANOVA).

Table (12): The difference between groups (A, B& C) in the bone formation scores on 15th, 30th and 45th post-operative days.

Time	χ^2 value	P-value	Sig.
On 15 th post-operative day	6.85	0.03	S
On 30 th post-operative day	12.5	0.002	S
On 45 th post-operative day	0.48	0.78	NS

* Sig.: significance * χ^2 : Chi-square *S: significant *NS: non significant

Table (13), reveals the differences between groups (A, B and C) in the bone formation on 15th and 30th postoperative days using Mann-Whitney test.

Table (13): Mann-Whitney test for the bone formation scores on 15th & 30th post-operative days.

Comparison	P-value	
	On 15 th post-operative day	On 30 th post-operative day
Group (A) vs. Group (B)	0.62 (NS)	0.62 (NS)
Group (A) vs. Group (C)	0.02 (S)	0.003 (S)
Group (B) vs. Group (C)	0.03 (S)	0.002 (S)

Discussion:

Many incidents of fracture occur every year world-wide and 5-10% of fractures experience delay in healing, even though treatment methods have improved over the past few decades⁹. Healing of bone fractures is an important homeostatic process that depends on specialized cell activation and proliferation during the period of injury repair¹⁰.

LLLT has been used to treat hard tissue injuries by promoting bone healing and alleviation of pain^{11,12}.

The results of the current study are consistent with that of *Queiroga et al.*², who conducted a study to assess the effect of laser therapy (660 and 780 nm) on the repair of the standardized bone defects on the femur of wistar albinus rats. The results showed that the group treated with laser therapy in the infrared spectrum resulted in an increase in the repair of bone defects when compared with the group treated with laser in the red spectrum and control group on 15th post-operative day.

These results are supported by *Sella et al.*¹³, who concluded that LLLT plays an important role in augmenting bone tissue formation, which is relevant to fracture healing. LLLT may therefore be indicated as an adjunct therapeutic tool in clinical practice for the treatment or recovery of non-union injuries.

Results are also documented by *Favaro-Pipi et al.*⁷, who found that laser therapy improves bone repair in rats as depicted by histopathological and morphometric analysis, mainly at the late stages of recovery. Moreover, it seems that this therapy was more effective than US to accelerate bone healing bone repair in rats as depicted by histopathological and morphometric analysis, mainly at the late stages of recovery. Moreover, it seems that this therapy was more effective than US to accelerate bone healing.

These results are also consistent with that of *De Vasconcellos et al.*¹⁴, who concluded that the GaAlAs infrared diode laser may improve the osseous integration process in osteopenic and normal bone, particularly based on its effects in the initial phase of bone formation.

These results come also in agreement with the study of *Ré Poppi et al.*¹⁵, who concluded that LLLT with wavelengths (660 nm and 880 nm) inhibited the inflammatory process and induced the proliferation of cells responsible for bone remodeling and repair.

The results of the current study are also come in consistency with that of *Pires-Oliveira et al.*¹⁶, who concluded that Low-level 904 nm laser (50 mJ/cm²) accelerated the repair process of osteopenic fractures, especially in the initial phase of bone regeneration.

The results are confirmed with that of *Hübler et al.*¹⁷, who found that LLLT had a positive effect on the biomodulation of newly formed bone.

Results are also, documented by *Son et al.*¹⁸, who found positive effects of LLLT in accelerating the bone healing process, especially in the early stage of bone formation.

Results are also documented by *Fazilat et al.*¹⁹ who found that a low level Ga Al As (810 nm; P, 200 mW) laser hastens new bone formation only in the early stages of the consolidation period in distraction osteogenesis, and has no significant effect in later stages.

Results are also documented by, *Barbosa et al.*²⁰ who concluded that, based on the radiographic findings; G (830nm) showed more complete bone regeneration than other two groups, G (control) and G (660nm).

Conclusion

It could be concluded that infrared laser showed a biostimulating effect on bone repair by stimulating the modulation of the initial inflammatory response and anticipating the resolution to normal condition at the earlier periods. However, there were no differences between groups on 45th post-operative day.

Acknowledgment

I would like to express my sincere thanks to **Dr. Nehal Ahmed Radwan**, Assistant professor of pathology, Faculty of Medicine, Ain Shams University, for her great help and cooperation.

Also, I wish to extend my sincere thanks to **Dr. Hossam El Din Mostafa Mohamed**, DVM, M.Sc., Manager of animal research United, NILES, Cairo University, for his great help and cooperation.

References

1. *Pretel; H., Lizarelli; R. and Ramalho; L.*: Effect of low- level laser therapy on bone repair: Histological study in rats, *Lasers in Surgery and Medicine*, 39:788-796, 2007.
2. *Queiroga; A., Sousa; F., Arujo; J., Santos; S. and Limeira; F.*: Evaluation of bone repair in the femur of rats submitted to laser therapy in different wavelengths: An image segmentation method of analysis, *Laser Physics*, 18(9):1087-1091, 2008.
3. *Ninomiya; T., Miyamoto; Y., Ito; T., Yamashita; A., Wakita; M. and Nishisaka; T.*: High-intensity pulsed laser irradiation accelerates bone formation in metaphyseal trabecular bone in rat femur. *J Bone Miner Metab.* 21(2):67-73, 2003.
4. *Garavello; I., Baranauskas; V. and Da Cruz-Hofling, M.*: The effects of low laser irradiation on angiogenesis in injured rat tibiae. *Histol Histopathol.* 19(1):43-48, 2004.
5. *Thanoon; M. and Ibrahim; S.*: Effect of bone marrow and low power lasers on fracture healing with destruction of both periosteum and endosteum in rabbits, *Iraqi Journal of Veterinary Sciences*, 24(1):5-9, 2010.
6. *Barbosa; D., De Souza; R., Xavier; M., Da Silva; F., Arisawa; E. and Villaverde, A.*: Effects of low level laser therapy (LLLT) on bone repair in rats: optical densitometry analysis, *Lasers Med. Sci.*, 28:651-656, 2013.
7. *Favaro-Pipi; E., Feitosa; S., Ribeiro; D., Bossini; P., Oliveira; P., Parizotto; N. and Renno; A.*: Comparative study of the effects of low-intensity pulsed ultrasound and low-level laser therapy on bone defects in tibias of rats, *Lasers Med. Sci.*, 25:727-732, 2010.

8. *Denadai, A.; Camargo, L.; Ribela, M.; Keeble, J.; Costa, S. and mascara, J.:* Participation of peripheral tachykinin NK1 receptors in the carrageenan induced inflammation of the rat tempromandibular joint. *EJP*, 13(8): 812-819, 2009.
9. *Kazem Shakouri, S.; Soleimanpour, J.; Salekzamani, Y. and Oskuie, M.:* Effect of low-level laser therapy on the fracture healing process. *Lasers Med Sci* 25: 73-77, 2010.
10. *Bashardoust Tajali, S.; Macdermid, J.; Houghton, P. and Grewal, R.:* Effects of low power laser irradiation on bone healing in animals: a meta-analysis. *J Orthop Surg Res* 5: 1-10, 2010.
11. *Nissan, J.; Assif, D.; Gross, M.; Yaffe, A. and Binderman, I.:* Effect of low intensity laser irradiation on surgically created bony defects in rats. *J Oral Rehabil* 33: 619-924, 2006.
12. *Matsumoto, M.; Ferino, R.; Monteleone, G. and Ribeiro, D.:* Low-level laser therapy modulates cyclooxygenase-2 expression during bone repair in rats. *Lasers Med Sci* 24: 195-201, 2009.
13. *Sella, V.; Do Bomfim, F.; Machado, P.; Morsoleto, M.; Chohfi, M. and Plapler, H.:* Effect of low-level laser therapy on bone repair: a randomized controlled experimental study. *Lasers Med Sci*, 30:1061-1068, 2015.
14. *De Vasconcellos, L.; Barbara, M.; Deco, C.; Junqueira, J.; Do Prado, R.; Anbinder, A.; Cairo, C. and Carvalho, Y.:* Healing of normal and osteopenic bone with titanium implant and low-level laser therapy (Ga Al As): a histomorphometric study in rats. *Lasers Med Sci*, 29:575-580, 2014.
15. *Ré Poppi, R.; Da Silva, A.; Nacer, R.; Vieira, R.; De Oliveira, L.; Junior, N. and Carvalho, P.:* Evaluation of the osteogenic effect of low-level laser therapy (808 nm and 660 nm) on bone defects induced in the femurs of female rats submitted to ovariectomy. *Lasers Med Sci*, 26:515-522, 2011.
16. *Pires-Oliveira, D.; Oliveira, R.; Amadei, S.; Pacheco-Soares, C. and Rocha, R.:* Laser 904 nm action on bone repair in rats with osteoporosis. *Osteopros Int*, 21:2109-2114, 2010.
17. *Hübler, R.; Blando, E.; Gaião, L.; Kreisner, P.; Post, L.; Xavier, C. and De Oliveira, M.:* Effects of low-level laser therapy on bone formed after distraction osteogenesis. *Lasers Med Sci*, 25:213-219, 2010.
18. *Son, J.; Kim, Y.; Ge, Z.; Choi, S. and Kim, G.:* Bone healing effects of diode laser (808 nm) on a rat tibial fracture model. *In Vivo*, 26:703-710, 2012.
19. *Fazilat, F.; Ghoreishian, M.; Fekrazad, R.; Kalhori, K.; Khalilil, S. and Pinheiro, A.:* Cellular effect of low-level laser therapy on the rate and quality of bone formation in mandibular distraction osteogenesis. *Photomedicine and Laser Surgery*, 32(6): 315-321, 2014.
20. *Barbosa, D.; Villaverde, A.; Arisawa, A. and De Souza, R.:* Laser therapy in bone repair in rats: analysis of bone optical density. *Acta ortop bras*, 22(2):71-74, 2014.
