

A Preliminary Study on Effects of Leaf Extract of *Ficus bengalensis* (Linn.) on Spermatogenesis and Fertility in Albino Mice

Prakash Chandra Gupta*

Department of Zoology, K. N. Government Post Graduate College, Gyanpur, S. R. N., Bhadohi (U. P.), 221 304, India.

*Corres.author: lightbhu@rediffmail.com
Mobile: +919453789926

Abstract: The oral administrations (200 and 500 mg/kg body weight/day for 35 days) of 50% ethanolic leaf extract of *Ficus bengalensis* (Linn.) had no effect on body weight, though, testes in extract-treated mice showed non-uniform histologic alterations in seminiferous tubules. The extract treatment at 500 mg/kg body weight for 35 days induced more severe alterations in the seminiferous tubules than at 200 mg/kg body weight. Sperm parameters were also severely affected in extract-treated mice in a dose-dependent manner. *F. bengalensis* treatment had no impact on libido of treated males, though, the number of live implants decreased significantly in females impregnated by males treated at 500 mg/kg body weight for 35 days. There were no histopathological alterations in liver, kidney, adrenal gland and spleen, and in serum levels of alanine aminotransferase, aspartate aminotransferase and creatinine in extract-treated mice compared to controls. The results suggest that *F. bengalensis* extract treatment causes suppression of the spermatogenesis and has adverse effect on sperm functions and fertility in treated mice in a dose-dependent manner without any toxic effects.

Keywords: epididymis; testis; spermatogenesis; sperm motility; seminiferous tubule.

Introduction

Plant and plant preparations have been used from ancient time for control of either male or female fertility in many countries including India. In recent years, however, much interest has been shown by scientists worldwide to control male fertility by using plants¹. This is because developing an antifertility agent from a plant source is cost effective and has low toxicity². Further, advantages of herbal contraceptives include the herbal preparation, their ready availability from local resources, and protection of privacy³. Therefore, the search for an orally active, safe, and effective herbal male contraceptive has become a matter of great interest in recent years.

Ficus bengalensis Linn. (Family: Moraceae), commonly known as 'Banayan tree' is a well known and reputed plant in ayurveda. In the traditional system of medicine, the plant is used for various health problems and diseases. Almost all parts of this plant are used in one or other way for medicinal purposes. The leaves are used to cure ulcer, aerial roots are used to treat gonorrhoea and seeds and fruits are used as tonic. The bark and latex are commonly used to cure hemorrhage, diarrhoea, and dysentery. Various extracts prepared from the bark of *F. bengalensis* show antihelmintic⁴, anti-inflammatory⁵, anti-stress and anti-allergic⁶ properties. The aqueous extract of bark of *F. bengalensis* has antidiabetic⁷, hypocholesterolaemic and hypolipidaemic effects⁸. However, the available literature on *F. bengalensis* has no report on the effect

of this plant on spermatogenesis in testes of male mice. In view of the fact that the plants may play an important role in regulation of fertility, the present study was carried out to evaluate the effects of chronic administration of 50% ethanolic leaf extract of *F. bengalensis* on spermatogenesis and fertility in albino mice.

Material and Methods

Plant material and preparation of extract

Fresh leaves of *F. bengalensis* were collected from local area after its scientific identification. The leaves were washed properly with distilled water, shade dried for one week, and then grounded into fine powder using an electric grinder. The powdered bark material (100 g) was extracted with 50% ethanolic water (2000 ml, w/v 1:20) for 8 hr by soxhlation⁹. The filtrate was concentrated in an oven at 40°C to get a blackish extract (20 g) that was stored at 4°C.

Animals and treatments

Fifteen adult (age 12-14 weeks) male mice weighing 30-34 g were used in the investigations. Animals were bred in our animal room under standard conditions (temperature 23±2°C and 12 hours photoperiod with proper ventilation) in polypropylene cages having dry rice husk as the bedding material, following the guidelines of Laboratory Animal Care (NIH Publication No. 85-23, 1985, USA). Animals were given pelleted feed and fresh drinking tap water *ad libitum*. Mice were randomly allocated into three groups, each comprising of five animals, as distilled water (0.5 ml/100g body weight/day) treated (Group I) and extract-treated (Groups II and III). *F. bengalensis* leaf extract was given orally, using an oral feeding needle, at the doses of 200 (Group II) and 500 (Group III) mg/kg/ body weight/day for 35 days. On day 36, animals in groups I, II and III were sacrificed together by decapitation after recording their final body weights. Serum, obtained by allowing the blood to clot at room temperature for 30 minutes followed by centrifugation at 3,000 rpm for 20 minutes, was used for estimations of alanine aminotransferase, aspartate aminotransferase and creatinine.

Histological techniques

For histological studies, testis, epididymis, a portion of liver, kidney, adrenal gland, and spleen were fixed in freshly prepared aqueous Bouin's fluid for 3 hours, dehydrated in graded ethanol series, cleared in benzene, and embedded in paraffin wax (60-62°C). Tissues were sectioned at 6µm, and sections were stained with periodic acid-Schiff (PAS) and counter

stained with Harris haematoxylin. The stained sections were examined under a Leitz (Germany) light microscope. Under qualitative study, histologic alterations occurred in seminiferous tubules of testis and in epididymis were studied while quantitative alterations in testis were analyzed by counting the number of affected tubules. Identification of stages of spermatogenesis in mouse testis was performed according to criteria described by Russell, Ettlín, Sinha Hikim, and Clegg¹⁰. For histological study, the epididymis was divided into five (I-V)¹¹ where segments I, II and III constitute caput, segment IV constitutes corpus and segment V constitutes caput of epididymis.

Serum biochemistry

Alanine aminotransferase (ALT) and aspartate aminotransferase (AST) activities were determined in serum according to the method of Reitman & Frankel¹². Serum level of creatinine was measured using commercial kit (Span Diagnostics Ltd., Surat, India).

Sperm analyses

Cauda epididymidis was taken out randomly from left or right sides of each of five animals from each group and placed in a watch glass containing 0.5 ml of 0.9% normal saline maintained at 37°C on a hot plate. The tissue was then minced and the sperm suspension, free of tissue debris, was used for analyses of motility, viability, and number of spermatozoa according to WHO Laboratory Manual¹³.

Fertility tests

Fifteen adult (age 12-14 weeks) male mice (Groups I, II & III) were employed in the fertility test. The fertility of extract-treated mice (administered the plant extract at 200 and 500 mg/kg body weight for 35 days) was tested together with the controls at 24 hr after cessation of the treatment. This was done by allowing each male to cohabit with one coeval, virgin female of proven fertility in proestrus for overnight. Mating was confirmed by presence of vaginal plug in the mated female. After 12/13 days of mating, the females were autopsied to record the total number of implantation (live, dead, and resorption) and corpora lutea in both the uteri and ovaries respectively. The males were considered fertile if the females impregnated by them showed live implants. The resorption sites were counted by putting the uterus in 10% ammonium sulphide solution¹⁴. Parameters such as index of libido in treated males and number of live implants, pre-implantation and post-implantation losses in impregnated females were determined.

$$\text{Index of libido} = \frac{\text{Number mated}}{\text{Number paired}} \times 100$$

$$\text{Pre-implantation loss} = \frac{\text{Total number of corpora lutea} - \text{total number of implantations}}{\text{Total number of corpora lutea}} \times 100$$

$$\text{Post-implantation loss} = \frac{\text{Total number of implantations} - \text{total number of viable implantation}}{\text{Total number of implantations}} \times 100$$

Statistical Analyses

All data, except those of body weight, were analyzed by one-way analysis of variance (ANOVA), followed by Neuman-Keuls' multiple range test. Data on body weight were analyzed by Student's t-test. Values were expressed as mean \pm SEM. Results were considered significant at $p < 0.05$ level.

Results

Body and organs weight

Treatment with *F. bengalensis* leaf extract did not cause any significant ($p < 0.05$) change in body weight and in general behavior of extract-treated mice compared to controls (Table 1).

Histology

Histologic observations of testes in distilled water-treated controls showed normal spermatogenesis (Figure 1 a) in nearly all the seminiferous tubules except in a few (see Table 2). On the other hand, detectable alterations were noticed in histoarchitecture of testes in mice treated with *F. bengalensis* leaf extract at 200 and 500 mg/kg body weight for 35 days (Figures 1 b-d). Alterations induced in testis were non-uniform as both affected and normal seminiferous tubules were observed in the same testis sections (Figure 1 c). Further, individual differences were also evident as some animals showed more severe alterations than others in their testes in treated groups (Groups II and III). In general, affected tubules in testes of extract-treated mice showed intraepithelial vacuolation, exfoliation of germ cells, presence of spermatids of different stages of spermatogenic cycle

in the same tubule and phagocytosis of elongated spermatids (Figures 1 b-c). However, mice treated with the plant extract at the dose of 500 mg/kg body weight (Group III) showed more alterations in their testes than those treated at the dose of 200 mg/kg body weight (Group II) for 35 days. The testes in mice treated at 500 mg/kg body weight for 35 days (Group III) often showed formation of multinucleated giant cells containing round or elongated spermatids in seminiferous tubules (Figure 1 d). When quantitatively analyzed, testes in *F. bengalensis* extract-treated mice showed a significant ($p < 0.05$) increase in frequency of affected seminiferous tubules compared to controls (Table 2). Further, frequency of affected seminiferous tubules was significantly high in testes of mice treated at 500 mg/kg body weight (Group III) than in those treated at 200 mg/kg body weight (Group II) for 35 days (Table 2).

In control mice, epididymes exhibited normal histological features (Figures not given). However, epididymes in *F. bengalensis* extract-treated mice in groups II and III showed presence of relatively less sperm or sperm fragments with accumulation of PAS-positive material in lumen of segments IV and V. Epithelial cells of segment IV of epididymes in two mice treated with *F. bengalensis* extract at 500 mg/kg body weight for 35 days showed distinct PAS-positive inclusions (Figures not given). Further, no histopathological alterations were noticed in liver, kidney, adrenal gland and spleen of *F. bengalensis* extract-treated mice compared to controls (Figures not given).

Table 1. Effect of 50% ethanolic leaf extract of *Ficus bengalensis* on body weight and serum levels of ALT, AST and creatinine in male mice.

Groups	Body weight (g)		ALT (U/L)	AST (U/L)	Creatinine (mg/100 ml)
	initial	final			
I Distilled water	31.2 ±0.48	32.0 ±0.31	23.45 ±2.56	26.72 ±0.17	1.55 ±0.18
II 200 mg/kg	31.2 ±0.48	31.6 ±0.50	20.45 ±2.93	24.51 ±0.86	1.59 ±0.06
III 500 mg/kg	30.8 ±0.48	30.4 ±0.24	31.07 ±6.08	24.51 ±3.11	1.99 ±0.10

Values are mean ± SEM for five animals.

Figure 1. PAS-H stained sections of mouse testis (Magnifications: a-c: X 200; e: X 252).

(a) Control to show normal spermatogenesis. (b) After treatment with *F. bengalensis* (200 mg/kg body weight for 35 days) to show intraepithelial vacuolation (arrow). (c) After the same treatment as in figure b to show presence of an affected tubule (asterisk) (d) After treatment with *F. bengalensis* (500 mg/kg body weight for 35 days) to show multinucleated giant cells containing round (arrow heads) or containing elongated spermatids (arrow). Note the active phagocytosis (small arrow) by Sertoli cells.

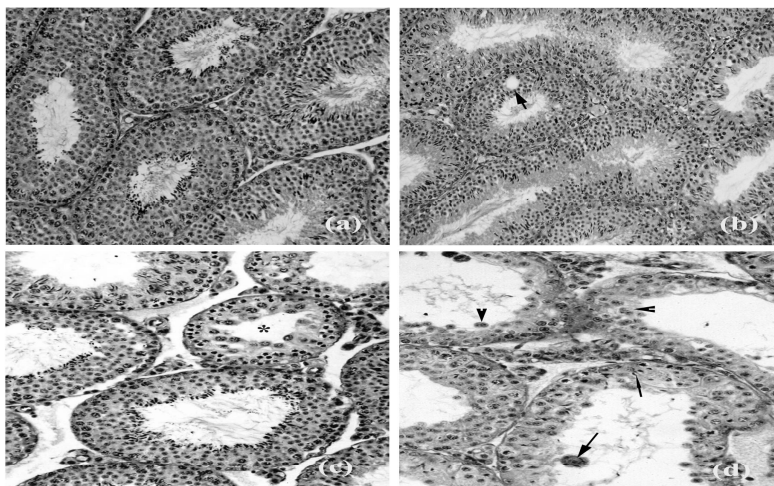
**Figure 1**

Table 2. Effect of 50% ethanolic leaf extract of *Ficus bengalensis* on motility, viability and number of sperm in caudae epididymidis, and on frequency of affected seminiferous tubules in testes of male mice.

Groups	Sperm parameters			Frequency of affected seminiferous tubules (%)
	Motility (%)	Viability (%)	Number (X 10 ⁶ /ml)	
I Distilled water	85.35 ±1.61	83.61 ±1.33	17.35 ±0.74	10.40 ±0.50
II 200 mg/kg	74.25* ±2.37	71.34* ±1.61	12.07* ±0.48	30.54* ±2.54
III 500 mg/kg	49.92 ^a ±5.60	65.13 ^a ±1.37	8.23 ^a ±0.76	45.59 ^a ±5.45

Values are mean ± SEM for five animals. * significantly different from controls (p<0.05); ^asignificantly different from controls and those in group II (p<0.05) by ANOVA followed by Newman-Keuls' multiple range test.

Table 3. Effect of 50% ethanolic leaf extract of *Ficus bengalensis* on libido of treated males and on pre- and post-implantation losses and number of live implants in impregnated females.

Groups	Number of males			Number of females			Index of libido (%)	Pre-implantation loss (%)	Post-implantation loss (%)	Number of live implants
	T	M	F	T	M	P				
I Distilled water	5	5	5	5	5	5	100	3.63±3.63	7.93±5.58	8.20±0.96
II 200 mg/kg	5	5	0	5	5	0	100	16.00±7.48	14.00±5.78	6.4±0.39
III 500 mg/kg	5	5	4	5	5	4	100	66.00*±10.76	6.66±6.66	2.80*±0.79

Values are mean ± SEM for five animals. * significantly different from controls (p<0.05) by ANOVA followed by Newman-Keuls' multiple range test. T- Tested; M- Mated; F- Fertile; and P- Pregnant

Serum biochemistry

No significant differences were found in serum levels of AST, ALT and creatinine in *F. bengalensis* extract-treated mice compared to controls (Table 1).

Sperm parameters

Significant (p<0.05) reductions were noticed in motility, viability, and number of spermatozoa in caudae epididymidis of *F. bengalensis* extract-treated mice (Groups II and III) compared to controls (Table 2). Further, reductions in sperm functions (motility, viability and number) were significantly high in mice treated at 500 mg/kg body weight (Group III) than in

those treated at 200 mg/kg body weight (Group II) for 35 days (Table 2).

Fertility tests

When *F. bengalensis* extract-treated males (Groups II and III) were allowed to cohabit with a virgin, regularly cycling proestrus female at 24 hr after cessation of the treatment, libido was not affected, though, impregnated females showed significantly reduced number of live implants when autopsied (Table 3). Pre-implantation loss was significantly high in the females impregnated by males treated with the plant extract at 500 mg/kg body weight for 35 days

compared to controls (Table 3). Further, post-implantation loss was not significant in the females impregnated by extract-treated males compared to controls (Table 3).

Discussion

The results of the present study indicate that treatments with *F. bengalensis* leaf extract (200 and 500 mg/kg body weight/day for 35 days) had no effect on body weight and on general behavior of extract-treated mice. Further, testes in extract-treated mice showed histologic alterations that were non-uniform as both affected and normal seminiferous tubules were observed in the same testis sections. It has been suggested that focal damages in testis occur because tubules in certain stages of spermatogenesis are more prone to damage by various treatments than the other. In general, affected tubules in testes of extract-treated mice showed intraepithelial vacuolation, exfoliation of germ cells, presence of spermatids of different stages of spermatogenic cycle in the same tubule and phagocytosis of elongated spermatids. Similar histologic alterations, as induced in testes of extract-treated mice in the present study, have also been observed in testes of mice after treatment with 50% ethanolic root extract of *Martynia annua*¹⁵. Further, mice treated with the plant extract at the dose of 500 mg/kg body weight showed more severe alterations in their testes than those treated at the dose of 200 mg/kg body weight for 35 days. The testes in mice treated at 500 mg/kg body weight for 35 days often showed formation of multinucleated giant cells containing round or elongated spermatids in seminiferous tubules. It has been reported that germ cells in the seminiferous tubules are connected with each-other by intercellular bridges¹⁶ and any alterations in the intercellular bridges results in the formation of multi-nucleated giant cells by fusion of germ cells. Furthermore, frequency of affected seminiferous tubules was significantly high in testes of mice treated at 500 mg/kg body weight than in those treated at 200 mg/kg body weight for 35 days. Therefore, it can be speculated that *F. bengalensis* leaf extract causes suppression of spermatogenesis in testis in a dose-dependent manner.

References

1. Chaudhury, S.R., Gupta, C.M. and Kamboj, V.P. Current Status in Fertility Regulation: Indigenous and Modern Approaches. Lucknow: Central Drug Research Institute 2001.
2. Chaudhury, R.R. Plant contraceptives: translating folklore into scientific application. In

Extract-treated mice showed accumulation of PAS-positive inclusions in the epithelial cells of segment IV of epididymis. Abe and his group^{17,18} have described that principal cells in segment II (caput) secrete PAS-positive material in the lumen which is utilized by sperm during maturation in subsequent segments, and that in absence of sperm, such material is reabsorbed by the principal cells of segment IV (corpus) of epididymis. Thus, presence of PAS-positive inclusions in epithelial cells of segment IV might be because of absence or reduced number of sperm in epididymal lumen. It is known that the structure and function of epididymis are dependent on androgens¹⁹ and testicular fluid is thought to influence the function of the epididymal duct²⁰. It can be speculated that the plant extract had no direct effect on the epididymal epithelium and histological alterations in the epididymis might be due to the suppression of androgen production in the testis. Thus, the reduced concentration of caudal spermatozoa in treated mice may be due to the suppressive effect of the extract on spermatogenesis, while alterations in sperm motility and viability might have resulted from disturbances in epididymal function²¹. The present study shows that treatment with *F. bengalensis* leaf extract had no impact on libido of extract-treated males, though, the number of live implants decreased significantly in females impregnated by males treated at the dose of 500 mg/kg body weight for 35 days. This could be probably because of severely altered number and motility of sperm in caudae epididymidis of above treated males. Further, absence of histopathological alterations in liver, kidney, adrenal gland and spleen, and in serum levels of ALT, AST and creatinine suggests that the treatment with the plant extract was not associated with any toxic effects.

The present results, thus, suggest that treatment with 50% ethanolic leaf extract of *F. bengalensis* caused suppression of the spermatogenesis in the testis and has adverse effect on sperm functions and fertility in albino mice in a dose-dependent manner without signs of clinical toxicity.

- Jelliffe B, Jelliffe, EEP, eds. Advances in Maternal and Child Health. Oxford: Oxford University Press 1985: 58-74.
3. Chaudhury, R.R. The quest for a herbal contraceptive. Natl Med J India 1993; 6 (5): 199-201.

4. Aswar, M., Aswar, U., Watkar, B., Vyas, M., Wagh, A. and Gujar, K.N. Anthelmintic activity of *Ficus bengalensis*. *IJGP* 2008; 2 (3): 170-172.
5. Patil, V.V., Pimprikar, R.B. and Patil, V.R. Pharmacognostical studies and evaluation of anti-inflammatory activity of *Ficus bengalensis* Linn. *Pharmacognosy* 2009; 1 (1): 49-53.
6. Taur, D.J., Nirmal, S.A., Patil, R.Y. and Kharya, M.D. Anti-stress and anti-allergic effects of *Ficus bengalensis* bark in asthma. *Nat Prod Res* 2007; 21 (14): 1266-70.
7. Gayathri, M. and Kannabiran, K. Antidiabetic and ameliorative potential of *Ficus bengalensis* bark extract in streptozotocin induced diabetic rats. *Indian Journal of Clinical Biochemistry* 2008; 23(4): 394-400.
8. Shukla, R., Anand, K., Prabhu, K.M. and Murthy, P.S. Hypocholesterolemic effect of water extract of the bark of Banyan tree, *Ficus bengalensis*. *Ind J Clin Biochem* 1995; 10: 14-18.
9. World Health Organization. WHO Chemical Guidelines, CG-03, 1001A/IP, Geneva 1986.
10. Russell, L.D., Ettlin, R.A., Hikkim, A.P.S. and Clegg, E.D. Histological and histopathological evaluation of the testis. Clearwater: Cache River Press 1990.
11. Takano, H. Qualitative and quantitative histology and histogenesis of the mouse epididymis, with special emphasis on the regional difference. *Acta Anat Nippon* 1980; 55: 573-587.
12. Reitmann, S. and Frankel, S. A colorimetric method for the determination of serum glutamate oxaloacetate and glutamic pyruvic transaminases. *Amer J Clin Pathol* 1957; 28: 56-63.
13. World Health Organization. WHO Laboratory Manual for the Examination of Human Semen and Semen-Cervical Mucus Interaction. Cambridge: Cambridge University Press 1999.
14. Salewski, E. Farbmethode zum makroskopischen Nachweis von Implantationssstellen am Uterus der Ratte. *Naunyn-Schmeidebergs Archiv fur Pharmakologie und Experimentelle Pathologie* 1964; 247: 367.
15. Mali, P.C., Ansari, A.S. and Chaturvedi, M., Antifertility effect of chronically administered *Martynia annua* root extract on male rats. *Journal of Ethnopharmacology* 2002; 82: 61-67.
16. Dym, M. and Fawcett, D.W. Further observations on the number of spermatogonia, spermatocytes, and spermatids connected by intercellular bridges in the mammalian testis. *Biol Reprod* 1971; 4: 195-215.
17. Abe, K., Takano, H. and Ito, T. Response of epididymal duct to the temporary deletion of spermatozoa induced by testicular irradiation in mice. *Anat Rec* 1983; 207: 17-24.
18. Abe, K., Takano, H. and Ito, T. Response of the epididymal duct in the corpus epididymidis to efferent or epididymal duct ligation in the mouse. *J Reprod Fert* 1987; 64: 69-72.
19. Cooper, T.G. The epididymis as a site of contraceptive attack. In Nieschlag E, Habenicht VF, eds. *Spermatogenesis, Fertilization, Contraception*. Berlin: Springer 1992: 419-460.
20. Fawcett, D.W. and Hoffer, A.P. Failure of exogenous androgen to prevent regression of the initial segment of the rat epididymis after efferent duct ligation or orchidectomy. *Biol Reprod* 1979; 20, 162-181.
21. Rajalakshmi, M. Regulation of male fertility: epididymis as a potential extragonadal site. In Ghosh D, Sengupta J, eds. *Frontiers in Reproductive Physiology*. New Delhi: Wiley Eastern Limited, 1992, 63-66.
