

Hsv infections in aids patients: need for awareness!!!

Uday Bhosale*, Dr. V. Kusum Devi, Mrs Nimisha Jain

AlAmeen College of Pharmacy, Bangalore 27, M.S., India.

Corres. Author: udaybhosale25@gmail.com

Abstract

Herpes simplex virus (HSV) has affected more than one third of the world's population and in India it is believed that 60% of sexually active adults carry herpes viruses. Approximately 45 million people in the US have HSV infections-about one in 5 people over the age of twelve. Severe persistent genital herpes was one of the first recognized opportunistic infections of acquired immune deficiency. In fact, from 60 to 85% of persons with HIV have HSV-2 antibodies. A recent study found that people with HSV had three times the risk of becoming infected with HIV as people without HSV. Currently the treatments available for herpes simplex are difficult and very rigorous so a new cost effective treatment modality for herpes simplex infections is the need of the day. Application of NDDS to such therapy will optimize the treatment by reducing dose, dosing regimen and associated side effects and patient discomfort.

What is Herpes?

Herpes simplex virus (HSV) is a member of the family of herpesviridae, a DNA virus (HSV) viz HSV type 1 and type 2.¹ HSV type 1 is the herpes virus that is usually responsible for cold sores of the mouth, the so-called "fever blister". HSV type 2 is the one that causes genital herpes. The infection causes painful sores on the genitals in both men and women. The disease lies dormant in nerve cells. But it may be reactivated by stress or illness.²

Herpes simplex virus (HSV) has affected more than one third of the world's population and is responsible for a wide array of human diseases, with effects ranging from discomfort to death.¹ In India it is believed that 60% of sexually active adults carry herpes viruses. Approximately 45 million people in the US have HSV infections-about one in 5 people over the age of twelve.³ The US Center for Disease Control (CDC)

estimate that there are one million new genital herpes infections each year. The rate of HSV infection has increased significantly in the past three years.³

While, it is estimated that 45 to 98% of adults have HSV-1 antibodies, the prevalence varies depending on geographic location, socioeconomic status and age. The Individuals from lower socioeconomic populations tend to have higher prevalence of HSV-1 antibodies and seroconvert earlier in life than the individuals from middle income populations. HSV-2 prevalence is also dependent upon various factors such as race, gender, marital status and place of residence. The overall HSV-2 seroprevalence is 10 to 40%, with a higher prevalence in blacks, females, divorced individuals and city residents.⁴

By virtue of sensitive nature of the clinical manifestation of this infection several thousand of cases have gone unnoticed /untreated especially in Indian scenario. The US center for Disease control (CDC) estimated that barely 20% of herpes patients/cases are currently identified.⁴

HSV infections are more common in women. It infects about one out of four women and about one out of five men. Genital HSV can cause potentially fatal infections in babies. If a woman has a active genital herpes at a delivery, a cesarean delivery is usually performed. Repeat outbreaks of HSV are most likely to occur in a people with a weakened immune system. This includes people with HIV disease and anyone over fifty years old.³

Herpes Simplex Virus

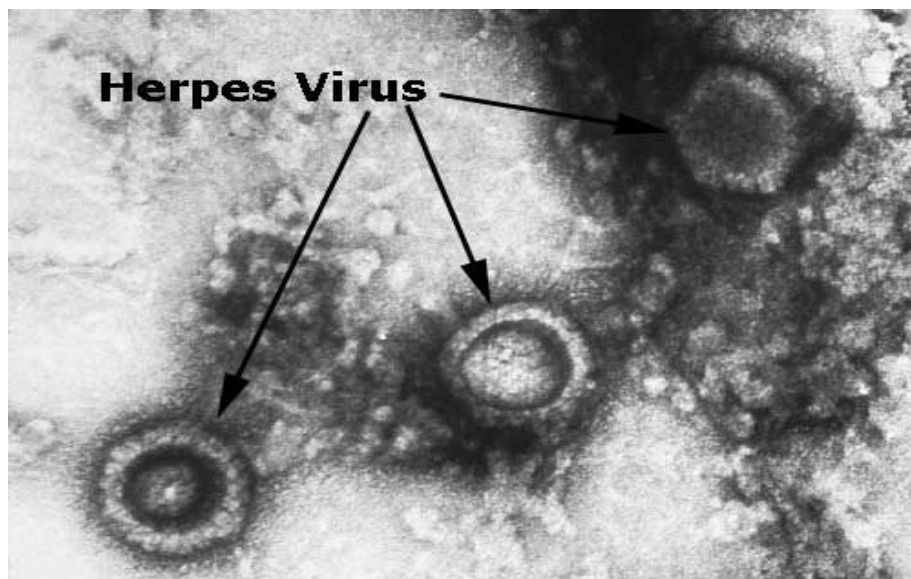


Photo Courtesy of CDC - Dr. John Hierholzer

Pathophysiology

HSV is spread by person to person transmission and enters the body through direct contact with the mucous membranes or abraded skin. Primary infection refers to first time exposure to either HSV-1 or HSV-2. After infection, the replication process involves many elaborate steps including adsorption, penetration, viral component synthesis, maturation and release. The replication at the site of primary / initial infection causes cell lysis and subsequent fluid filled blisters or ulcers.

After viral replications at the site of infection, HSV is transmitted within sensory neurons via retrograde movement, usually to the trigeminal or sacral ganglia, where it undergoes another round of replication before establishing latency.⁶ A latent virus may be reactivated by fever, tissue damage, emotional stress, ultraviolet light or other immunosuppressive triggers to cause recurrent infections. Studies have demonstrated that HSV-2 is often transmitted during times of asymptomatic shedding, which may partially explain the continued increase in HSV – 2 transmissions.

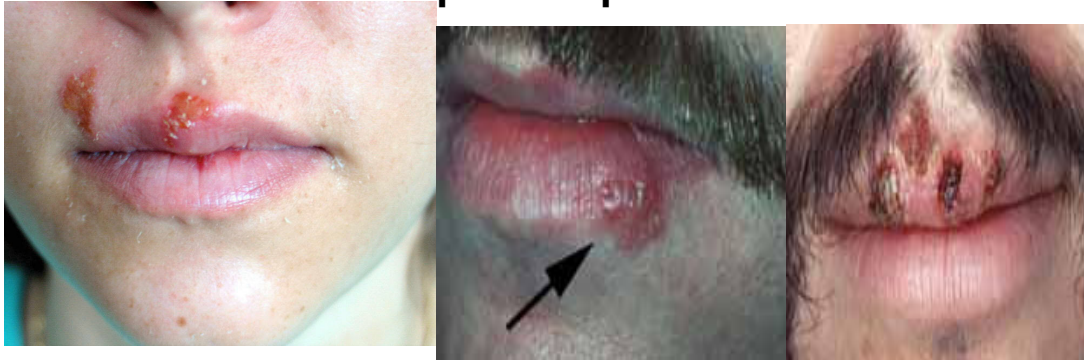Clinical presentation

In general, asymptomatic primary orofacial HSV infections occur more frequently than symptomatic primary infections. Patients with herpes labialis usually experienced less than 2 recurrent infections per year.⁶ Primary genital HSV infections, however, are more commonly associated with clinical symptoms. The following discussion describes common symptoms of HSV infection, although the severity and frequency of symptoms vary greatly among individuals.

1. Orofacial Herpes Simplex Virus Infection

Symptomatic primary orofacial infection most commonly presents as fluid filled vesicles on the tongue plate, pharynx and buccolabial membranes (gingivostomatitis) and may produce red, swollen and bleeding gums. Adults commonly experienced pharyngitis and mononucleosis- like syndrome. Other symptom of primary orofacial infections includes sore throat, difficulty eating and swallowing, malaise and tender cervical lymphadenopathy. Recurrent orofacial infections are usually preceded by a prodrome of pain, burning, tingling or itching, which last of approximately 6 hours before vesicles appear. Pain is most severe during the first 3 to 4 days while complete healing can take as many as 8 to 10 days.

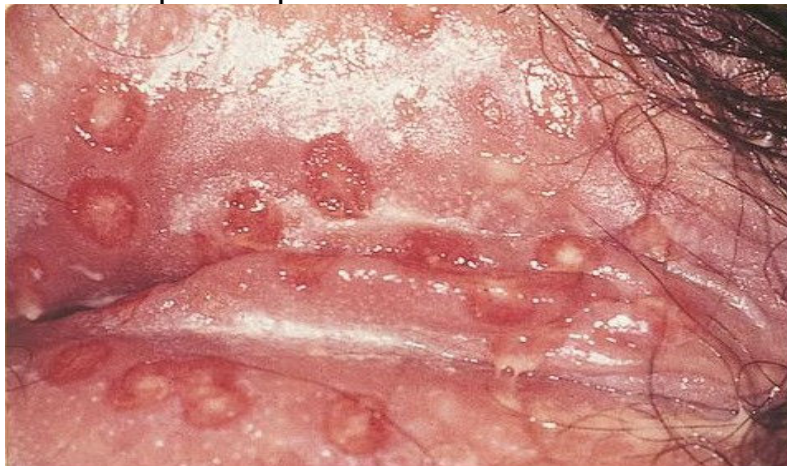Orofacial Herpes Simplex Virus Infection

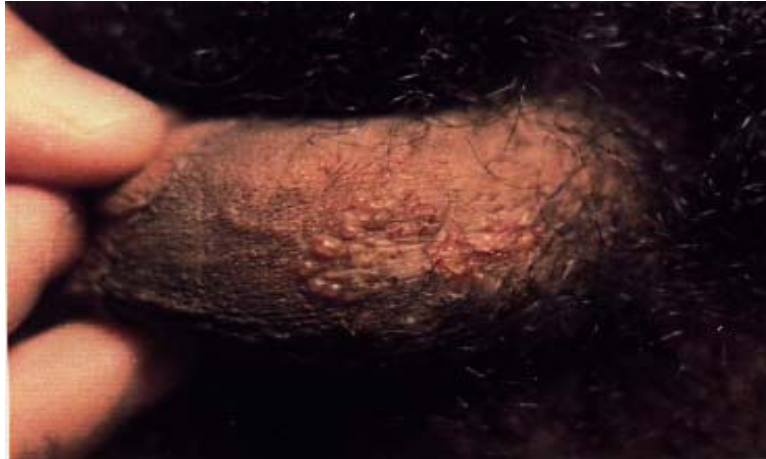

2. Genital Herpes Simplex Virus Infection :

Primary genital infections are associated with systemic symptoms such as fever, headache, malaise (feeling of general discomfort or uneasiness, an "out of sorts" feeling, often the first indication of an infection or other disease) and myalgia (Muscular pain or tenderness, typically of a diffuse and/or nonspecific nature). Primary genital HSV infections present as macules and papules which progress to vesicles and ulcers before healing . In women, lesions are extremely painful and appear bilaterally on the vulva and also involve the cervix, vagina, buttocks and perineum. Women are also more prone to experience urinary retention syndrome or aseptic meningitis. Men usually exhibit lesion on the glans penis and | or the penile shaft although lesion may also appear on the thigh, buttocks and perineum. Recurrent infections are typically less severe than initial infection and may be preceded by prodromal symptoms prior to lesion formation. The lesion usually resolves in 8 to 10 days.

Genital Herpes Simplex Virus Infection Women & Men





HSV and HIV

Sever persistent genital herpes was one of the first recognized opportunistic infection of acquired immune deficiency. In fact, from 60 to 85% of persons with HIV have HSV-2 antibodies.⁵ Herpes sore provides away for HIV to get past the body's immune defense and make it easier to get HIV infection. A recent study found that people with HSV had three risk of becoming infected with HIV as people without HSV.³

There are some important facts that HIV person who are HSV-2 infected should recognize that, genital lesion due to HSV-2 are associated with brining large amount of HIV virus to the mucosal surface and appears to result in the ability to transmit HIV (as well as HSV) to other more efficiently.⁵ sub clinical reactivation of HSV increases HIV-1 in rectal secretion. So most authorities feel that all HIV positive persons should have a management plan for their genital herpes if they are HIV-2 seropositive.⁵

Does HSV-2 infection Enhance HIV-1 Transmission

Data on mucosal interaction of HIV and HSV-2 suggsted that HIV-1 seropositive, and HSV-2 seropositive person may transmit HIV infection more frequently than HIV-1 seropositive person who are HSV-2 seronegative.² It is noteworthy that the presence of recent symptomatic genital ulceration in the HIV positive source partner significantly increased the transmission probability per act (0.0041) when compared with no ulceration (0.0011). Because HSV-2 is the most common cause of genital ulceration in this population, it suggested that HSV-2 may enhance transmission of HIV from symptomatic dually infected persons.²

Is HIV-1 replication influenced by HSV?

Several studies have evaluated the influence of HSV reactivation on plasma HIV-1 RNA in association with genital lesion . Two recent studies that evaluate sub clinical HSV shedding , suggest HSV-2 significantly influence the replication of HIV-1. Schacker et al. directly studied the influence of HSV infection on HIV-1 replication in vivo by administering chronic daily therapy with acyclovir to HIV/HSV-2 co-infected person and measuring plasma HIV-1 RNA levels before and after administration of acyclovir.² Acyclovir reduced plasma RNA levels an average of one third of log; a reduction in plasma HIV RNA levels was observed in 11 of 12 persons and HIV-1 RNA levels return to previous baseline upon discontinuation of therapy.⁶

Can herpes be prevented?

It is difficult to prevent the spread of HSV. Partly this is because many infected people don't know that they carry HSV and can spread it. Even people who know they are infected with HSV may not realize they can transmit the infection even without an open herpes sores.³ The herpes virus can also be spread by touching the sores and then touching another part of the body. If you touch the sores, wash your hands with soap and water as soon as possible .also do not share towels or clothing with anyone.⁷

To keep away herpes from spreading, intimate contact should be avoiding when sores are on the body. Itching burning or tingling may occurs just before the sores develop. Sexual intercourse should be avoided during this time.⁸ Condoms can reduce the rate of HSV transmission. However, they can not prevent it. HSV infections can be transmitted to and from a large genital area, such as that area covered by "boxer shorts" and also around the mouth.³

Drugs companies are working on vaccines to prevent HSV. No vaccines have been approved yet to prevent HSV infections but research is going in this area.

Antiviral Drugs against Herpes Infections

Since its discovery 20years ago, acyclovir has remained the antiviral drug of choice for the treatment of genital herpes. Acyclovir has proved to be effective and well tolerated as compared to other drugs. Due to its poor oral bioavailability(less than 20%) the compound must be given as a five times daily regimen, which can lead to compliance issue.⁶ Therefore , new agents with improved bioavailability has been developed and these are now being used. These drugs are valacyclovir, the valine ester of acyclovir and

famciclovir, the diacetyl 6 deoxy prodrug of penciclovir.³ The indications and dosages of these drugs are summarized in table no. 1

Even though addition of new antiherpes drugs (famciclovir and valacyclovir), Acyclovir has been the original gold standard of therapy, remains a widely prescribed and reliable drugs.⁴

Aciclovir, efficacy and tolerability

The mechanism of action of acyclovir results in a high degree of clinical efficacy as well as good tolerability. Once acyclovir enters the cell it is monophosphorylated by virally-induced thymidine kinase. Therefore, only cells harbouring HSV, effectively phosphorylate acyclovir to its activated triphosphosphate moiety. Host cellular kinase are responsible for transforming the mono-phosphorylated aciclovir into the activated triphosphorylated form.

Acyclovir triphosphate then competitively binds irreversibly to viral DNA polymerase and thus prevents the formation of DNA replication complex. Aciclovir triphosphate may also be incorporated into the growing chain of viral DNA where it promotes chain termination because it lacks the 3' hydroxyl group required for incorporation of the next nucleotide.⁷ While all acyclic nucleoside analogues inhibit herpesvirus DNA polymerase, acyclovir triphosphate has been found to be 100 times more potent as inhibitor of HSV polymer than others, for example, penciclovir triphosphate.

1. Oral herpes

Treatment of herpes labialis with acyclovir has produced inconsistent result. In adults, acyclovir has been shown to be an effective prophylactic agent during high risk trigger events such as snow skiing. There was a 74% reduction in recurrent infections in patients who use oral acyclovir prior to and during skiing, although this was not a universal finding.⁸ For general suppression of frequent recurrences (six or more per year), prophylactic oral aciclovir has been shown to reduce both the number of clinical episodes and the amount of viral shedding by 53% and 71%, respectively.

2. Genital herpes

Acyclovir has become the mainstay of therapy for genital herpes. Topical acyclovir 5% ointment is more effective during primary episodes than initial (non primary) or recurrent episodes. When used during primary infection, topical acyclovir decreased duration of viral shedding, time of local pain and time of crusting. It was less

effective in preventing new lesion formation or decreasing time to overall healing. Topical acyclovir, in general, did not prove beneficial for recurrent genital HSV infections. In sharp contrast, intravenous acyclovir is very effective in decreasing the time of viral shedding, time to healing, the number of new vesicles and duration of symptoms. However, intravenous acyclovir is usually reserved for severe disease in immunocompetent patients.

Oral acyclovir is the most commonly used preparation of acyclovir and is useful in primary/ initial, recurrent and suppressive therapy of genital HSV infections. The course of disease during a first episode (primary and non primary) is greatly affected by oral acyclovir. It consistently decreased time of viral shedding by 100% to 60%, reduced time to crusting by 67% to 30%, reduced time to healing by 45% to 25%, decreased new lesion formation 100% to 71%, and reduce symptoms (pain and itching) by 56% to 29%. During recent episodes, oral acyclovir has been shown to reduce time of viral shedding by 50 % to 32% and reduce time to healing by 21% to 15%. Early initiation of therapy has a greater impact on the course of the disease^{8,9}.

More recently, oral acyclovir has been shown to be an effective suppressive therapy when taken for extended periods (up to 5 years) in patients with frequent recurrences of genital HSV. Long term suppressive therapy has decreased the number of recurrences by 86% to 63% and increased the time to first recurrence 4.6 to 13.6 fold.

Before the advent and use of triple antiretroviral therapies, oral acyclovir (600 to 800 mg/day) in combination with zidovudine was shown to reduce mortality in patients with AIDS. Clinical experience indicates that oral acyclovir, in dosages ranging from 600 to 800 mg/day, is effective in suppressive therapy for frequent recurring HSV disease in HIV infected people⁸.

Among antiviral agents, acyclovir has an enviable tolerability profile. The drug has been used for over 15 years by over 30 million people worldwide, and yet there have been no reports of death or serious irreversible adverse reactions associated with its use. The most frequent reported adverse effects during acyclovir therapy are headache, nausea, diarrhea, and abdominal pain/ cramping. 30 clinical trials evaluating 3364 patients found no statistically significant differences between acyclovir and placebo for either mild or major adverse events. A transient increase in serum urea and creatinine levels was reported in patient who received acyclovir as an intravenous bolus⁹. There have been several other reports of reversible nephrotoxicity associated with acyclovir when administered high intravenous doses⁹.

Future potential for NDDS in antiherpes treatment

It is because of physicochemical properties viz low solubility, low bioavailability and site specific absorption of antiviral agents .For example, acyclovir has oral bioavailability of 10-30%,⁹ the half life is about 3 hrs in adults and drugs is soluble only at acidic pH (pKa 2.27), limiting its absorption in GIT to duodenum and jejunum.⁹ So in view of the difficulties associated with adhering to therapy with the presently available conventional dosage forms, a new cost effective treatment modality for herpes simplex infections is the need of the day. Application of NDDS to such therapy will optimize the treatment by reducing dose, dosing regimen and associated side effects and patient discomfort.

Table 1: Antiherpes drugs for the treatment and prophylaxis of genital herpes⁶

Indications	Dosing regimen
First episode , treatment with	
Acyclovir	200mg, 5 times daily for 5-10 days
Valacyclovir	1g , twice daily for 5-10 days
Famciclovir	
Recurrent episode, treatment with	
Acyclovir	400mg twice daily for 5 days
Valacyclovir	500mg twice daily for 5 days
Famciclovir	125-250mg twice daily for 5 days
Recurrent disease treatment with	
Acyclovir	400mg twice daily
Valacyclovir	500mg twice daily
Famciclovir	250mg twice daily

References

1. World Health Organization. Herpes simplex virus type 2 programmatic and research priorities in developing countries, WHO/HIV_AIDS/2001.05. Report of a WHO/UNAIDS/LSHTM Workshop, 14–16 February 2001, London.
2. Centers for Disease Control and Prevention. Sexually Transmitted Diseases Treatment Guidelines 2002, 51.

3. World Health Organization. Guidelines for the management of sexuallyB transmitted infections, Revised version.WHO/RHI/01.10 2003. Geneva: WHO, 2003.
4. Fleming DT, McQuillan GM, Johnson RE, et al. Herpes simplex virus type 2 in the United States, 1976 to 1994. *N Engl J Med* 1997;337:1105–11.
5. Pebody RG, Andrews N, Brown D, et al. The seroepidemiology of herpes simplex virus type 1 and 2 in Europe. *Sex Transm Infect* 2004;80:185–91.
6. Weiss H. Epidemiology of herpes simplex virus type 2 infection in the developing world. *Herpes* 2004;11:A24–35.
7. Paz-Bailey G, Rahman M, Chen C, et al. Changes in the etiology of sexually transmitted diseases in Botswana between 1993 and 2002: implications for the clinical management of genital ulcer disease. *Clin Infect Dis* 2005;41:1304–12.
8. Plummer FA, D’Costa LJ, Nsanze H, et al. Clinical and microbiologic studies of genital ulcers in Kenyan women. *Sex Transm Dis* 1985;12:193–7.
9. Greenblatt RM, Lukehart SA, Plummer FA, et al. Genital ulceration as a risk factor for human immunodeficiency virus infection. *AIDS* 1988;2:47–50.
