

## Lucio Phenomenon mimicking with Vasculo necrotic Erythema Nodosum Leprosum: A Case Report

Dwi Sepfourteen<sup>1\*</sup>, Tutty Ariani<sup>2</sup>

<sup>1</sup>Department of Dermatology-Venereology, School of Medicine, Medical Faculty  
of Andalas University, Padang, West Sumatera, Indonesia

<sup>2</sup>Department of Dermatology-Venereology, Head of Infection Division, Dr. M.  
Djamil Hospital, Medical Faculty of Andalas University, Padang, West Sumatera,  
Indonesia

**Abstract :** Clinical features of Lucio's phenomenon (LP), shows a nectorizing erythema, may mimicking Erythema Nodosum leprosum with vasculonecrotic. A 46 years old man presented with diagnosis lepromatous leprosy with Lucio's phenomenon and diferential diagnosis borderline lepromatous (BL) with vasculonecrotic erithema nodosum leprosum. The patients complained there were painless ulcers on his lower limbs and scrotum, with surrounded by purpuric patches which subsequently became gangrenes and ulcerated for 3 weeks. There was numbness of both hands and feet, the eyelashes, eyebrows baldness since 5 years ago. Patient never got the treatment before. Bacteriological examination showed bacterial index 6+ Histopathology: there were Flattened epidermis by narrow grenz zone, and lymphocyte in perivascular with macrophage. There was endothelial proliferation of capiller. Fite faraco stain showed macrophage infiltration around the perivascular, with colonization of the endothelial cell by acid fast bacilli and epidermal necrosis and diagnosis as Lepromatous leprosy with Lucio phenomenon. This patient is given adult multiple drug therapy (MDT) therapy, methylprednisolone, neurotrophic vitamins. Lucio's phenomenon most commonly affects patients with untreated leprosy. Clinically, it may be difficult to differentiate Lucio phenomenon from Erythema nodosum leprosum with vasculonecrotic. In this case, the histopathological examination were colonization of endothelial cell by acid fast bacilli, epidermal necrosis and endothelial proliferation of the vessel.

**Keywords :** *lepromatous leprosy, Vasculonecrotic, ENL.*

## Introduction

Lucio Phenomenon (LP) is a special type of reaction observed in uniformly diffuse shiny infiltrative non-nodular form of LL leprosy, called as Lucio leprosy which is chiefly encountered in Mexicans. Its unique feature is that it is seen only in untreated cases. This form of leprosy and its unique form of reaction were described by Lucio and Alvarado in Mexico in 1852 and later, by Latapi and Zamora in 1948. It has also been reported from other countries such as Costa Rica, the USA, Hawaii, and Brazil. Few cases of lucio leprosy have also been reported in the recent past from India, Spain, Malaysia, Iran, South afrika And Singapore.<sup>1,2</sup>

Lucio phenomenon usually occurs in patients who have received either no treatment or inadequate treatment. In contrast to ENL, fever, tenderness, and leukocytosis are absent. The lesions consist of barely palpable, hemorrhagic, sharply marginated, irregular plaques. They develop into crusted lesions and, particularly on the legs, into ulcers. There may be repeated attacks or continuous appearance of new lesions for years. Histopathologically, In the Lucio reaction, vascular changes are critical. Endothelial proliferation leading to luminal obliteration is observed in association with thrombosis in the medium-sized vessels of the dermis and subcutis. There is a sparse, largely mononuclear infiltrate. Dense aggregates of acid-fast bacilli are found in the walls and the endothelium of normal-appearing vessels as well as in vessels with proliferative changes. Ischemic necrosis, brought on by the vascular occlusion, leads to hemorrhagic infarcts and results in crusted erosions or frank ulcers.<sup>3</sup>

The etiopathogenesis of this phenomenon is less well understood. *M. leprae* are found unusually in large numbers in the endothelial cells of superficial blood vessels, and this finding may be responsible for the serious vascular complications seen during the reactive phase. There is marked vasculitis and thrombosis of the superficial and deep vessels resulting in hemorrhage and infarction of the skin. Lucio phenomenon might be another unusual variant of ENL, like necrotizing ENL.<sup>4</sup>

Several hypotheses about the pathogenesis of Lucio's phenomenon have been proposed. One hypothesis is that patients with Lucio's phenomenon have a severe immune response deficiency, free replication of *M. leprae* in endothelial cells, and enhanced exposure of mycobacterial antigen to circulating antibodies, resulting in vasculitis and infarction due to infiltration of the endothelium by *M. leprae*. Others report that such free replication of *M. leprae* would mechanically cause vascular thrombosis, necrosis and all the subsequent alterations described. Some authors believe that Lucio's phenomenon is mediated by deposition of immune complexes in dermal blood vessels, known as the Arthus phenomenon.<sup>5</sup>

Erythema nodosum leprosum (ENL) occurs most commonly in LL and less frequently in BL leprosy. It may be observed not only in patients under treatment but also in untreated patients. Classical histopathological features of active ENL lesions of the skin are increased vascularity with dilated capillaries in the upper dermis, and in the lower dermis, an intense infiltration with neutrophils which have predilection for surrounding blood vessels and invading the walls. There is edema of the endothelium of veins, arterioles and small arteries. In case of erythema necroticans there is obliterative angitis and endarteritis. Bacilli are few and are mostly fragmented and granular.<sup>1,3</sup>

The standard method for confirmation of diagnosis of leprosy is by histopathological examination of tissue sections from the advancing margin of an active lesion. Histopathology are include confirmation of diagnosis in a clinically ambiguous or suspect case, including special stains and immunohistochemistry, diagnosis of a reaction state, differentiation of type 1 from type 2 reactions and relapse, accurate classification by defining the spectral position of a given case for the purpose of therapy and research. assessment of disease activity, response to therapy including cure, application of the technique related to immunology and molecular biology.<sup>1</sup>

## Case Report

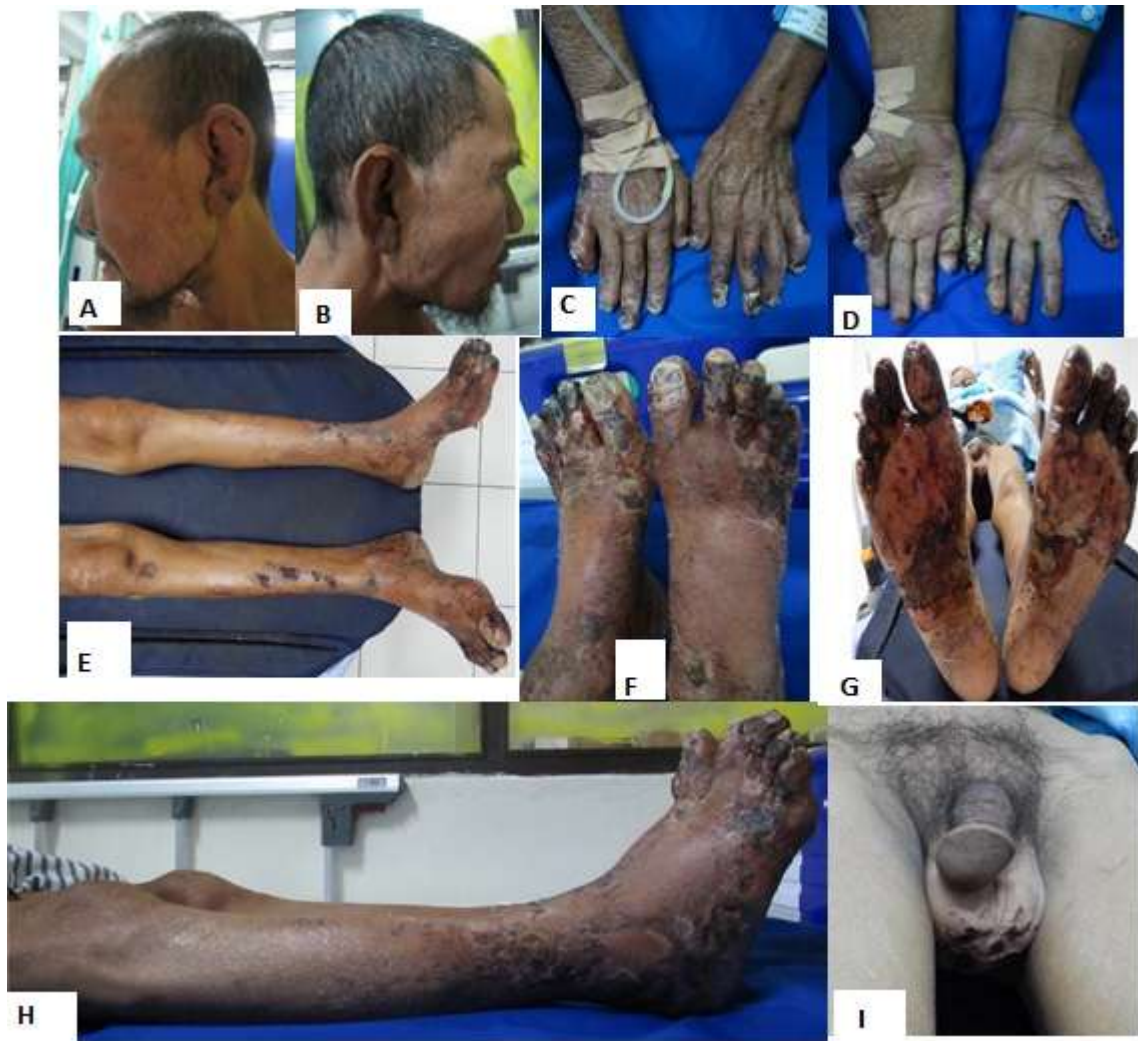A 46-year-old man with a chief complaint extensive painful purpuric infarcts with necrotic ulcer on hand and the legs since three weeks ago. Ulcers on both feet were wet with a purulent discharge. The scrotal skin was also gangrenous. He presented with history of fever five days ago and he had noted facial swelling and thickened ear lobes since 2 years ago. He did not seek any medical care. He had shiny facial skin with complete loss of eyebrows and eyelashes. There was stiffness of nose or clogged since 2 years ago. There was baldness of

eyebrows, eyelashes and eye dryness since 2 years ago. Fingers on right hand and toes became crooked and shorter since 2 years ago. Patient often feel exhausted, and lost his appetite since 1 year ago.

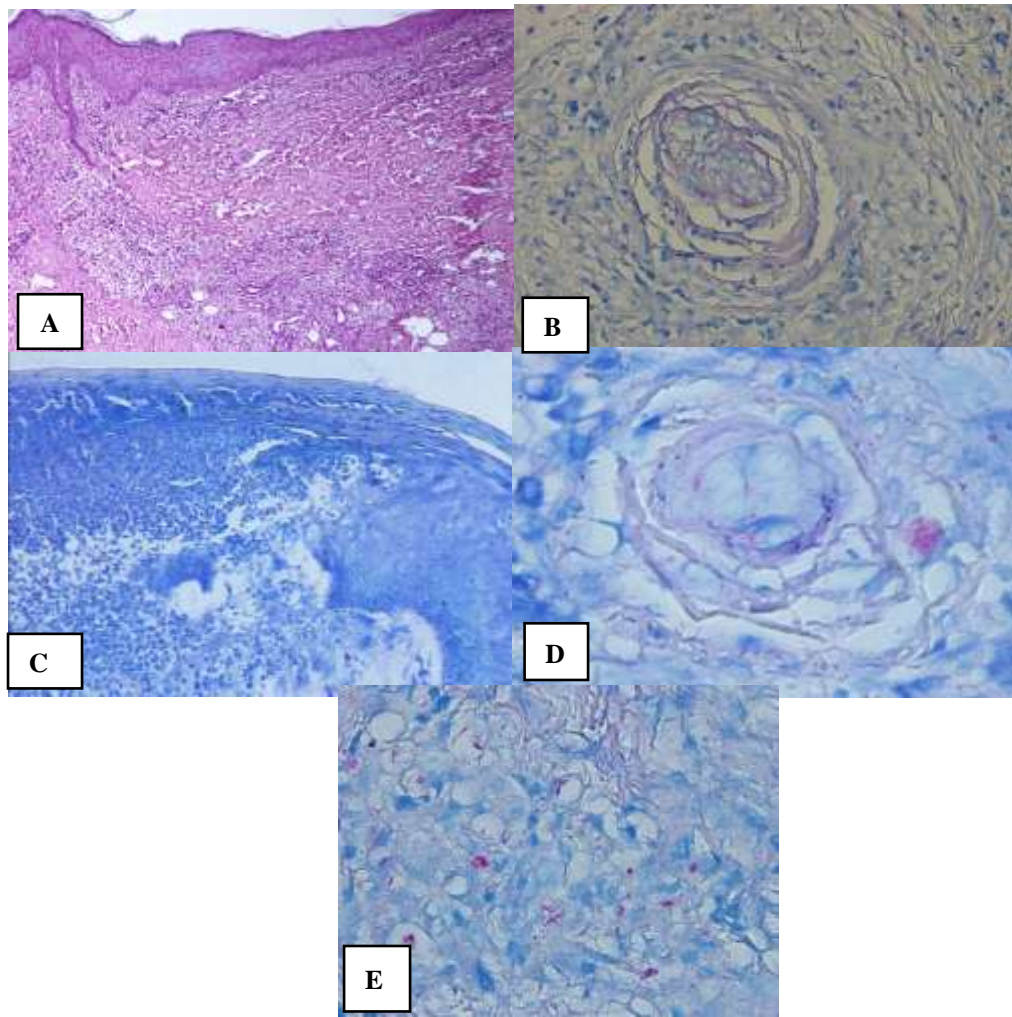
Physical examination revealed an afebrile man with confluent, sharply marginated, purpuric patches on both legs, which subsequently became gangrenous and ulcerated. He also had multiple, irregularly shaped, angulated, purpuric macules on the forearms, hands, feet, palms, and soles. His face and ears were diffusely infiltrated with madarosis. The sensory loss is symmetrical (glove and stocking anesthesia).

Slit skin smear revealed a bacteriologic index (BI) of +6 and a morphologic index (MI) of 2.0. Significant laboratory findings included low hemoglobin at 8.8 g/dL, hypoproteinemia, and hypoalbuminemia. Biopsy of a purpuric leg lesion revealed extensive necrotizing leukocytoclastic vasculitis and numerous foamy histiocytes with globi of acid-fast bacilli (AFB) in the dermis and subcutis, endothelial proliferations confirming a diagnosis of Lucio's phenomenon.

Dapsone (100 mg/day), rifampicin (600 mg/day), and clofazimine (100 mg/day) were started immediately, together with prednisolone (32 mg/daily) for the reaction. He also received erythromicine for secondary infection with *Staphylococcus aureus*. All the purpuric irregularly shaped macules became brownish and healed without scarring; however, the ulcers on both lower limbs required multiple debridement and eventually healed with skin grafting.



**Figure 1.** Skin manifestations of Lucio's phenomenon. A&B. both of ears were diffusely infiltrated and necrosis.C-I. Purpuric patches on both of hands, both of legs and scrotum which subsequently became gangrenous and ulcerated.



**Figure 2. Histology of the skin biopsy. A. Flattened epidermis) by narrow grenz zone. B. Showed endothelial proliferation of capillar (Fite Stain 40x).C. Showed necrosis in epidermis (Fite Stain.10x).D. Macrophage and endothelial cells of the capillary contain acid-fast bacilli (Fite Stain 100x). E. Acid Fast bacilli (AFB).**

## Discussion

We reported a case of lepromatous leprosy (LL) with Lucio's phenomenon (LP). The location of biopsy was taken from purpuric leg lesion. Clinical differential diagnosis on the patient is borderline lepromatous leprosy with vasculonecrotic erythema nodosum leprosum (ENL). The diagnosis of LP is basically made on clinical grounds, based on the findings of erythematous, geometric, irregular-shaped skin lesions predominantly affecting the upper and lower extremities that progress to ulceration and necrosis, appearing in LL or BL patient, with acid fast bacilli (AFB) demonstrated in skin specimens or earlobe smears. Associated with the clinical picture, the histopathology of the lesions presents characteristic findings as previously described, which reinforce the diagnosis.

Our first impressions when we look at the lesions, there was confusions whether this patient suffered BL or LL type with lucio's phenomenon. Borderline Lepromatous consists numerous skin lesions that classically distinct but not so well defined, not symmetrical distribution, signs of nerve damage within the lesion such as loss of sensation, decreased sweating and hair growth start sooner in BL than in LL. Eyebrows are either not involved or are lost partially. Symmetrical anesthesia involving hands and feet does not develop till late the disease and usually there are no symptoms to oral cavity or eyes. Lepromatous leprosy in early lesions, there are small macules, innumerable in number, disseminated and distributed symmetrically yet the infiltration is clinically not very obvious. Diffuse lepromatous leprosy usually has a shiny look with slight



infiltration, the thickness of skin is most marked over the face especially the forehead, earlobes, eyebrow, nose and malar surface. The sensory loss is symmetrical and is first detected over the extensors of forearms, legs, hands and feet, which gradually results in the typical glove and stocking anesthesia.

Lucio's phenomenon most commonly affects patients with untreated leprosy, but has been reported in those on irregular treatment. It is characterized by intermittent crops of irregularly shaped erythematous or purpuric macules or plaques with sharply marginated serrated borders. These lesions evolve into hemorrhagic infarcts and, subsequently, ulcers that heal with atrophic stellate scars. Vesicles or bullae are occasionally noted. Skin lesions are most frequently located on the legs, less frequently on the thighs and forearms, and rarely on the face and trunk. Fever, arthritis, elevated ESR, lymphadenopathy, hepatosplenomegaly, glomerulonephritis, anemia, hypoalbuminemia, and hypocalcemia have been described. Differential diagnoses include septic vasculitis, such as necrotizing fasciitis, cutaneous or systemic vasculitides, and other causes of thrombotic vasculopathy. Lucio's phenomenon usually appears between 1 and 3 years after the first manifestation of the disease<sup>6,1</sup>

In our patient, based on anamnesis Our patient present with non nodular diffuse skin infiltration, loss of eyebrows and eyelashes, and thickening of the upper eyelids which is giving the patient a sleepy or melancholy look. In addition, there was history of rhinitis or nasal clogged since 2 years. Our patient had symptoms and signs suggestive of leprosy for between 5-6 years, there was no history of taking any leprosy treatment before. On physical examination, there is no visible lesions that evident in her trunk, upper arms and legs. However, we still make observations by pinching the skin, palpate to check whether there is a thickness of skin. We performed the touch and pain test, the patient loss of sensation symmetrical. there is bilateral madarosis. Dermatological state, we found necrotic, infiltrat on the two of earlobe, some of the lesions are necrotic, dark, irregular-shaped lesions, coalescent and ulcerated on upper and lower extremities. acid fast bacilli demonstrated in ulcer specimens or earlobe smears with bacterial index was +6. Somehow, all the clinical symptoms in this patient exhibited to the lepromatous leprosy with Lucio's phenomenon.

The most laboratory abnormalities occur in Lucio's phenomenon are anemia, an elevated erythrocyte sedimentation rate, hypoalbuminemia, hypergammaglobulinemia, mild lymphopenia, which is compatible in our patient. We performed the cultured, and *staphylococcus aureus* as interpreted as a secondary infection by bacteria and sensitive to erythromicine antibiotic.

Histopathologically, Lucio's phenomenon has been reported to have two types of patterns. One of them involves leukocytoclastic vasculitis as the underlying pathologic change, and the other, endothelial cell proliferation, thrombosis, a mild mononuclear cell infiltrate and ischemic necrosis. The first pattern is thought to be due to an immune complex disease caused by *M. leprae* or skin antigens. In the second pattern, vascular damage is thought to be due to direct invasion of *M. leprae*.<sup>7,8</sup>

Rea and Ridley have compared the histology of vasculonecrotic ENL and lesions of Lucio phenomenon. They distinguish Lucio phenomenon from vasculonecrotic ENL ischemic epidermal necrosis, necrotizing vasculitis of small blood vessels in the upper dermis, severe focal endothelial proliferation of mid-dermal vessel, and by presence of large numbers of bacilli in endothelial cells. A comparative account of clinical features of lucio phenomenon and vasculonecrotic ENL has been presented by Leticia et al, in LP histopathology shows colonization of the endothelial cell by acid fast bacilli, ischemic epidermal necrosis, necrotizing vasculitis of the small vessels of the superficial dermis, endothelial proliferation of the medium sized vessels of the mid-dermis with passive venous congestion, and neutrophilic infiltration. In ENL with vasculonecrotic histopathology shows panvasculitis, it starts in the hypodermis, where the affected vessels are of variable caliber, with larger necrosis resulting in fibrotic scars.<sup>9</sup>

Histopathology examination result in this patient found epidermal necrosis, endothelial proliferation of capiller, macrophage infiltration around the perivascular, with colonization of the endothelial cell by acid fast bacilli. The histopathological findings were similar to those described in the literature for Lucio's phenomenon.

Histopathology examination can distinguish between lepromatous (LL) leprosy with borderline lepromatous (BL) leprosy. In borderline-lepromatous leprosy there are small collections of macrophages rather

than epithelioid cells. Macrophages may show slight foamy change. Lymphocytes are present in dense clumps or are widely distributed in parts of the granuloma; a few epithelioid cells may be seen occasionally. The formation of small granulomas is characteristic of BL and granulomatous regions may about strands of normal looking but heavily bacillated Schwann cells. A grenz zone is present in both borderline-lepromatous and true lepromatous leprosy. Bacilli are easily found. Lepromatous leprosy is characterized by collections and sheets of heavily parasitized macrophages within the dermis, with a sparse sprinkling of lymphocytes. Rarely, subcutaneous and deep dermal inflammatory are present. In older lesions the macrophages have a foamy appearance (lepra cells, Virchow cells). The characteristic of borderline-lepromatous are epithelioid cell. Contrast with lepromatous leprosy, epithelioid cell was not found. In this case, histopathology examination was found flattened epidermis by narrow grenz zone and dermis there were lymphocyte in perivascular with macrophage (no granuloma formation) and epithelioid cell was not found.<sup>10,8</sup>

Among the various hypotheses proposed for the pathogenesis of Lucio's phenomenon, most accepted is free replication of *M. leprae* in endothelial cells, and enhanced exposure of mycobacterial antigen to circulating antibodies, resulting in vasculitis and infarction. In LP lesion, the triggering event was a thrombotic/occlusive condition, with few inflammatory components, which was probably elicited by the alterations of endothelial cells secondary to their massive bacillary invasions. Endothelial hyperproliferation and edema have also been reported. This initial event would lead to the narrowing of the lumen of the small vessels, hypoxia, culminating the development of necrosis. LP lesions predominate in the lower limbs, followed by face, trunk and lower limbs. This is probably due to association with local predisposing factors, such as stasis, congestion, lower temperature and eventually a thrombophilic state. LP has frequently been described during pregnancy or puerperium, conditions well known to be associated with a thrombophilic state, as we saw in the present case. However, once necrosis ensues, a secondary inflammatory response takes place with attraction of inflammatory cells and deposition of immune complexes and other inflammatory mediators, the overall picture described as a leukocytoclastic vasculitis. This is probably the histopathology picture frequently seen in biopsies of LP, which is mistaken for the initiating process. Thus, the overlap between severe ENL and LP may be due, as earlier suggested by some investigators, to the location and timing of the biopsy. If done when the process is well established, an inflammatory process is found, which likely corresponds to the secondary response to the tissue necrosis.<sup>11,5</sup>

There is no specific treatment for Lucio's phenomenon. All multibacillary leprosy cases are treated with a MDT-MB (multi drug therapy) on the World Health Organization (WHO) recommended therapy of monthly rifampicin 600 mg, clofazimine 300 mg together with dapsone 100 mg/ day and clofazimine 50 mg/day and metilprednisolone 32 mg with tapering off. The response to treatment and prognosis of Lucio's phenomenon appear to be poor, except in the series by Rea and Jerskey, where all 30 patients studied survived the reaction. Lucio's phenomenon has an aggressive and rapid course, resulting in death in many reported cases. For instance, Golchai et al. reported a patient from Iran who died of sepsis. From Brazil, Souza et al. described four cases with one mortality in 2000, and Costa et al. reported another case that succumbed to sepsis in 2005.<sup>1</sup>

## Conclusion:

Lucio's phenomenon is rare and high index of suspicion is needed to diagnose the condition. Diagnosis was based on anamnesis, physical examination, laboratory and histopathology examination, observed diffuse non-nodular form of lepromatous leprosy, the stocking glove pattern of sensory impairment due to lead debilitating tropic changes of the feet, hair lost in the eyebrows, eyelashes. A case of Lucio phenomenon that clinically and histopathology can differentiated from ENL vasculonecrotic wich showed epidermal necrosis, endothelial proliferation of capillar, macrophage infiltration around the perivascular, with colonization of the endothelial cell by acid fast bacilli.

## References

1. Choon SE, Tey KE. Lucio's phenomenon: A report of three cases seen in Johor, Malaysia. *Int J Dermatol*. 2009;48(9):984–8.
2. Kaur C, Thami GP, Mohan H. Lucio phenomenon and Lucio leprosy. *Clin Exp Dermatol*. 2005;30(5):525–7.
3. Ang P, Tay YK, Ng SK, Seow CS. Fatal Lucio's phenomenon in 2 patients with previously undiagnosed

- leprosy. J Am Acad Dermatol. 2003;48(6):958–61.
4. Herath S, Navinan MR, Liyanage I, Rathnayaka N, Yudhishdran J, Fernando J, et al. Lucio's phenomenon, an uncommon occurrence among leprosy patients in Sri Lanka. BMC Res Notes. 2015;8(1):4–9.
  5. Thappa DM SP. Leprosy reaction: Pathogenesis and clinical features. India. In: IAL textbook of leprosy. Jaypee the health sciences; 2017. p. 483–91.
  6. Suvirya S, Pathania S, Malhotra KP, Jain A, Verma P, Kumari P. A case of diffuse lepromatous leprosy with Lucio phenomenon. Qjm. 2020;113(2):138–9.
  7. Monteiro R, Tiezzi MG. Lucio ' s phenomenon : another case reported in Brazil Fenômeno de Lúcio : mais um caso relatado no Brazil. 2012;87:296–300.
  8. Rea TH, Ridley DS. Lucio's phenomenon: a comparative histological study . IntJLeprOther MycobactDis . 1979;47(0148-916X):161–6.
  9. Lucio phenomenon (necrotizing erythema) in patients with Lucio leprosy: A case report. J Am Acad Dermatol. 2016;74(5):AB151.
  10. Sehgal VN. Lucio's phenomenon/erythema necroticans. Int J Dermatol. 2005;44(7):602–5.
  11. Benard G, Sakai-Valente NY, Bianconcini Trindade MA. Concomitant lucio phenomenon and erythema nodosum in a leprosy patient: Clues for their distinct pathogeneses. Am J Dermatopathol. 2009;31(3):288–92.

\*\*\*\*\*