



## Clinicopathological changes in equine herpes virus type 1 (EHV-1) infection in Arabian foals

Fararh K.M.<sup>1</sup>, Kandil O.M.<sup>2</sup>, Abd-Allah O.A.<sup>3</sup> and Thabet N.F.<sup>4\*</sup>

<sup>1</sup>Department of Clinical Pathology, Faculty of Veterinary Medicine, Banha University, Egypt

<sup>2</sup>Department of Animal Reproduction & Artificial Insemination, Veterinary Research, Egypt. Division, National Research Center, Egypt

<sup>3</sup>Department of Clinical Pathology, Faculty of Veterinary Medicine, Sues Canal University, Egypt

<sup>4</sup>Department of Veterinary Care, El-Zahra Stud for Egyptian Arabian Horses Breeding, Egypt

**Abstract:** Evaluate clinicopathological changes in Arabian foals infected by EHV-1 are important for equine clinics to help in supportive clinical and earlier detection of complication. Blood sample were collected from sixty foals for haematological and biochemical determination. Growing foals (n = 60): divided into apparently healthy animals (n = 17), vaccinated animals (n = 8) which vaccinated with Equine Herpes Virus type 1, and EHV-1 diseased animals (n = 35) were suffered from respiratory disease disorders. Recovered animals (n = 35) were the same diseased animals but after disappear of respiratory symptoms. The present work was reported mild immune mediated hemolytic anemia in diseased and recovered (three weeks after) foals groups. WBCs differential showed neutropenia, lymphocytosis, monocytosis and eosinopenia in diseased and recovered (three weeks after) foals groups while vaccinated animal showed lymphocytosis. Hypoproteinemia was found in diseased, recovered (three weeks after) and vaccinated foals groups. Hypoalbuminemia and hypoglobulinemia were observed in diseased foals group. GOT and GGT revealed significant increase in vaccinated foals group. In conclusion, present work reported clinicopathological changes associated with of EHV-1 in Arabian foals.

**Keywords:** EHV-1, haematological, biochemical determination, Arabian foals.

### Introduction

Equine herpes viruses (EHVs) are ubiquitous, contagious viral equine pathogen that most frequently causes abortion, fatal neonatal illness, or neurologic disease<sup>1</sup>. It is classified among the alpha (EHV-1, EHV-3 and EHV-4) and gamma (EHV-2 and EHV-5)<sup>2</sup>. Alpha herpes viruses (EHV-1 and EHV-4) are the most important in the domestic horse population which are responsible for sporadic respiratory disease, abortion and myeloencephalopathy<sup>3,4</sup>.

EHV-1 have a major economic and welfare impact on all sectors of the horse industry worldwide through their direct clinical effect on the horse, including respiratory disease, abortion<sup>5</sup> and paralysis<sup>6</sup> and through their effect on the horse industry, including interference with horse movement for breeding and competition.

During the outbreaks in particular, it is important to select rapid, sensitive, and specific diagnostic test to enable rapid implementation of biosecurity measures and limit disease spread, either by direct demonstration of infection (virus isolation, virus antigens, nucleic acid or histopathology) or indirect evidence of infection (hematology or serology) <sup>2</sup>. In practice, the usual approach of diagnostic laboratories of Equine Herpes Virus-1 either by hematological and biochemical tests as well as PCR, virus isolation and identification are to make an initial, perhaps preliminary and rapid diagnosis.

The ability to evaluate clinicopathological changes in horses infected by EHV-1 is important for equine clinicians. Accurate and rapid laboratory confirmation of Equine Herpes Virus-1 infection allow more effective supportive clinical management, earlier detection of complications, more accurate prognosis, more effective isolation protocols, evaluation of vaccination programs, detection of vaccination failures, and probably in the future, selection of supportive and appropriate antiviral drugs.

## **Material and Methods**

### **1. Animals and Study design:**

Sixty samples were collected from a cohort of Arabian horses located in El Zahraa stud, Cairo, Egypt, in the years 2012 and 2013 which are well feed with alpha alpha and barley. All horses were growing foals (n =60) aged from 6 months to 2 years, divided into apparently healthy foals (n = 17), vaccinated foals (n = 8) which vaccinated with Equine Herpes Virus type 1 and diseased foals (n = 35) were suffered from fever, respiratory disorders. Recovered foals (n = 35) were the same diseased foals but after disappear respiratory symptoms (three weeks after).

### **2. Blood sample for Clinicopathological examinations:**

Venous blood samples were collected from the jugular vein of horses and transferred immediately into sterile vacuum tubes.

#### **2.1- Hematological studies:**

Sterile vacuum tube (with dipotassium salt of EDTA) used for haematological studies included erythrogram (hemoglobin concentration, packed cell volume, RBCs count, MCV, MCH and MCHC), leukogram (total leukocytic count and differential leukocytic count) and platelets count. Hematological parameters were measured by using automated hematology analyzer (Celtac alpha, Nihon kohden MEK-6450, Tokyo, Japan). Thin blood smears were air-dried and stained by Giemsa stain and examined erythrocyte shape under oil immersion lens.

#### **2.2. Biochemical parameters examinations:**

Sterile vacuum tube (plain) used for estimation of biochemical parameters. The collected blood samples were allowed to clot and serum samples were obtained by centrifugation at 3000 rpm for 15 minutes. Serum were obtained by plastic aspirating pipette and transferred into clean dry labelled Eppendorf tubes and kept in deep freeze till examination. Serum sample were used for quantitative determination of total protein, albumin, ALP, AST and GGT. Kits for Biochemical studies were obtained from Centronic GmbH, Germany.

### **3. EHV-1 diagnosis using PCR :**

Samples were taken via sterile swabs from the nasal cavities of foals group and collected on virus transport medium. These swabs were used for PCR studies.

Semi-Nested PCR was used to determine EHV-1. The use of polymerase chain reaction (PCR) was according to<sup>7,8</sup>. The primer sequences were according to<sup>9</sup>.

#### **Principle:**

Prepared template DNA from test specimens using kit (High Pure PCR Template Preparation Kit, Roche Molecular Biochemical and Indianapolis, USA).

Nested primer sequences specific for EHV-1:

- BS-1-P1 = 5'-TCTACCCCTACGACTCCTTC-3' (917–936)
- gB1-R-2=5'-ACGCTGTCGATGTCGTAACCTGAGAG-3'(2390–2363)
- BS-1-P3 = 5'-CTTTAGCGGTGATGTGGAAT-3' (1377–1396)
- gB1-R-a = 5'-AAGTAGCGCTTCTGATTGAGG-3' (2147–2127)

PCR conditions for first stage amplification: Specimen template DNA (1–2 ug in 2 µl) is added to a PCR mixture (total volume of 50 µl) containing 1 × PCR buffer, 200 µM of dNTP, 2.5 mM MgCl<sub>2</sub>, 2.0 µM of each EHV-1 primer and 0.5 u Taq DNA polymerase. Cycling parameters are: initial denaturation at 94°C for 4 minutes; 40 cycles of 94°C for 30 seconds, 60°C for 30 seconds, and 72°C for 90 seconds; with a final extension at 72°C for 10 minutes. Separate reaction mixtures containing either known viral DNA or no DNA (water) should be prepared and amplified as positive and negative controls. Gel analysis of amplified products according to<sup>10,11</sup>, electrophoresed of PCR product through an agarose gel and stained with ethidium bromide, the amplified DNA appear as white bands in the gel.

#### 4. Statistical analysis:

The obtained data were analyzed with statistical software package SPSS for Windows, Version 22. Statistical analysis was carried out with one way ANOVA test.

## Result

### 1. Hematological analysis:

#### 1.1. Erythrogram:

The RBCs count, packed cell volume (PCV) and hemoglobin concentration (Table 1, Figure 1 - 6) was significantly decreased in diseased and recovered foals groups while vaccinated foals group showed non-significant decreases in RBCs, in comparison with control group. The mean corpuscular hemoglobin concentration (MCHC) showed a significant increase in diseased, recovered and vaccinated foals groups if compared with control group. The mean corpuscular hemoglobin (MCH) and the mean corpuscular volume (MCV) revealed non-significant changes in diseased, recovered and vaccinated foals groups if compared with control group.

Changes in erythrocytes morphology (Fig.7), erythrocyte spherocytosis, erythrocyte auto-agglutination and ghost erythrocytes were observed in the blood film of diseased and recovered foals group.

**Table (1): Changes in erythrogram profile in foals groups (mean ± SE)**

Parameter	Foals Groups			
	Control	Vaccinated	Diseased	Recovered
RBCs x10 <sup>12</sup> /l	10.14±0.50 <sup>b</sup>	9.33±0.23 <sup>ab</sup>	8.05±0.44 <sup>a</sup>	7.65±0.44 <sup>a</sup>
HCT %	33.75±1.31 <sup>b</sup>	32.96±0.64 <sup>b</sup>	27.41±1.35 <sup>a</sup>	26.89±1.32 <sup>a</sup>
Hb g/dl	11.82±0.24 <sup>c</sup>	11.39±0.25 <sup>bc</sup>	10.68±0.26 <sup>ab</sup>	10.25±0.28 <sup>a</sup>
MCV fl	34.01±0.99 <sup>a</sup>	35.41±0.65 <sup>a</sup>	36.68±0.99 <sup>a</sup>	36.64±0.89 <sup>a</sup>
MCH pg	12.69±1.47 <sup>a</sup>	12.23±0.21 <sup>a</sup>	13.45±0.84 <sup>a</sup>	15.42±1.59 <sup>a</sup>
MCHC g/dl	33.96±0.12 <sup>a</sup>	34.55±0.18 <sup>b</sup>	35.71±0.09 <sup>d</sup>	34.98±0.12 <sup>c</sup>

a, b and c: There is no significant difference ( $P < 0.05$ ) between any two means for the same attribute, within the same row have the same superscript letter.

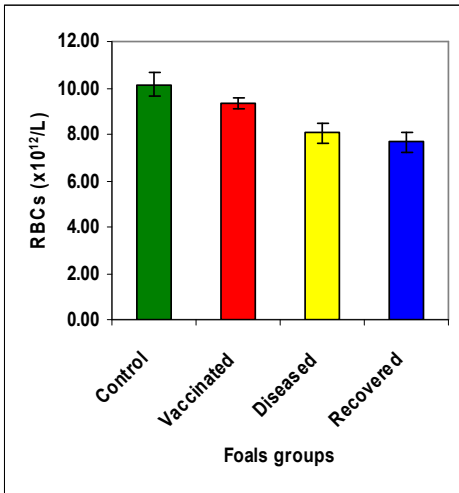


Figure (1): Changes in RBCs count

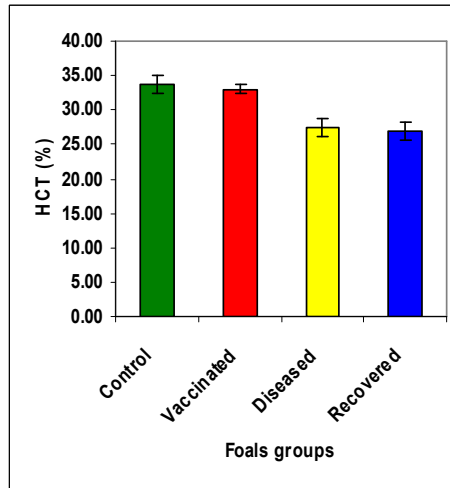


Figure (2): Changes in HCT %.

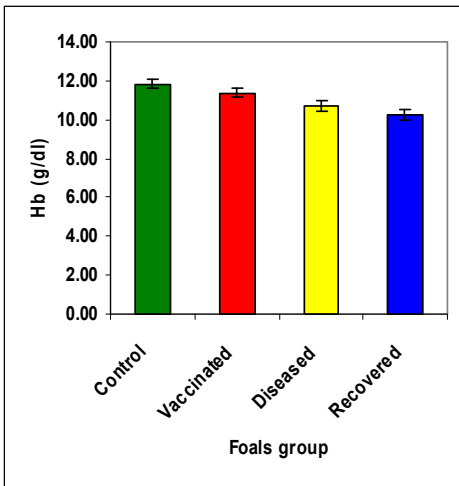


Figure (3): Changes in Hb concentration.

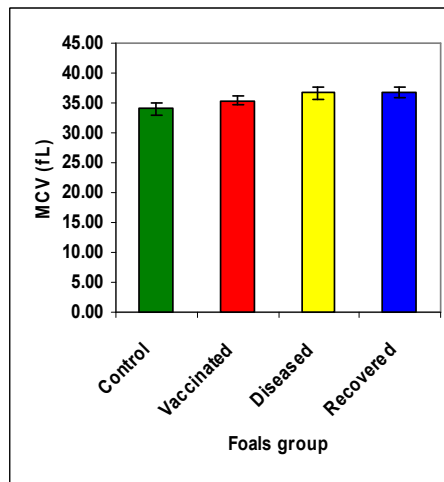


Figure (4): Changes in MCV.

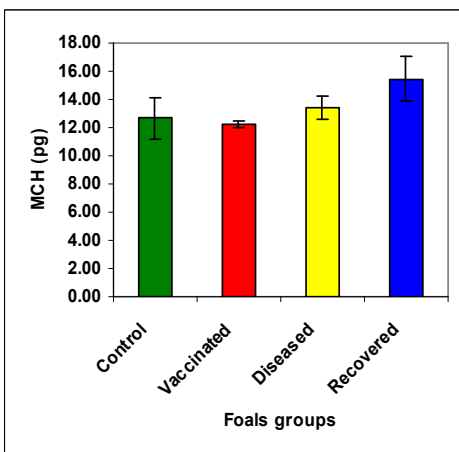


Figure (5): Changes in MCH.

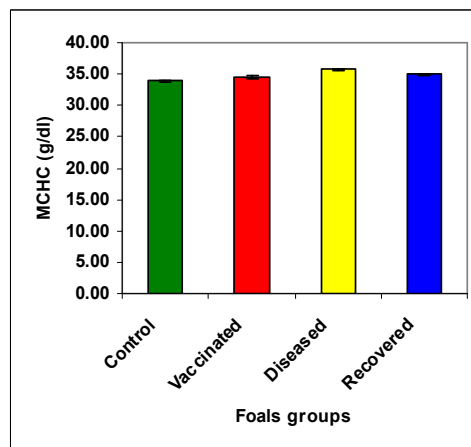
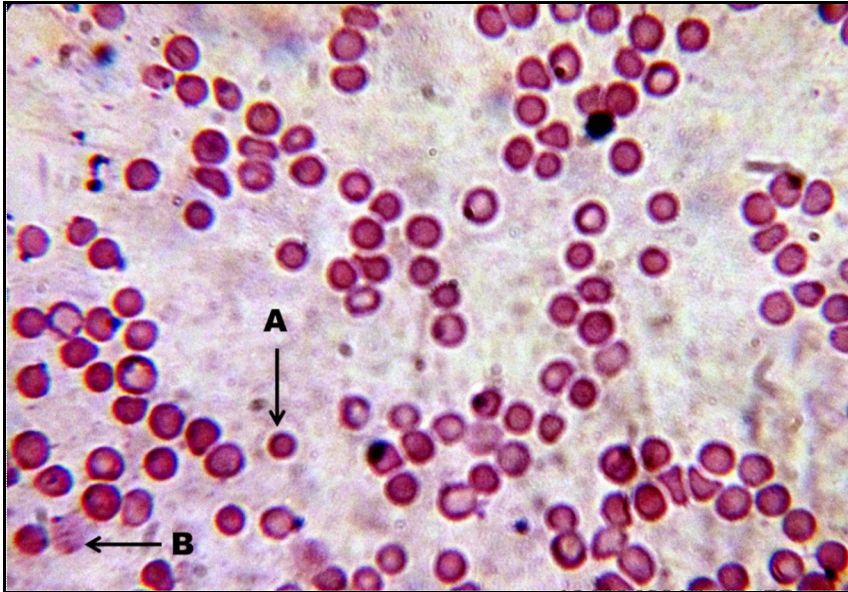


Figure (6): Changes in MCHC.



**Fig 7 : Blood film from foal with respiratory disease caused by EHV-1. (A) Erythrocyte spherocytosis. (B) Ghost erythrocytes.**

### 1.2. Leukogram and platelets:

The granulocytes and the eosinophils (Table 2, Figure 8 – 13) showed a significant decrease in diseased and recovered foals groups and non-significant decrease in vaccinated foals group, in comparison with control foals group. The monocytes showed a significant increase in diseased and recovered foals groups and a significant decrease in vaccinated foals group, in comparison with control foals group. The lymphocytes showed a significant increase in diseased, recovered and vaccinated foals groups when compared with control group. The total WBCs count and the platelets were revealed non-significant changes in all foals groups, if compared with the control.

**Table (2): Changes in Leukogram and platelets in foals groups (mean  $\pm$  SE).**

Parameter	Foals Groups			
	Control	Vaccinated	Diseased	Recovered
WBCs $\times 10^9/l$	11.18 $\pm$ 0.38 <sup>a</sup>	11.56 $\pm$ 0.67 <sup>a</sup>	11.56 $\pm$ 0.33 <sup>a</sup>	10.85 $\pm$ 0.42 <sup>a</sup>
Granulocytes %	49.05 $\pm$ 2.05 <sup>b</sup>	46.08 $\pm$ 1.70 <sup>b</sup>	38.1 $\pm$ 1.20 <sup>a</sup>	34.77 $\pm$ 1.10 <sup>a</sup>
Lymphocytes %	38.85 $\pm$ 1.58 <sup>a</sup>	45.18 $\pm$ 1.83 <sup>b</sup>	46.98 $\pm$ 1.37 <sup>b</sup>	52.59 $\pm$ 1.04 <sup>c</sup>
Monocytes %	4.38 $\pm$ 0.91 <sup>b</sup>	2.26 $\pm$ 0.29 <sup>a</sup>	8.35 $\pm$ 0.21 <sup>d</sup>	6.75 $\pm$ 0.09 <sup>c</sup>
Eosinophils %	7.43 $\pm$ 1.09 <sup>b</sup>	6.36 $\pm$ 0.38 <sup>ab</sup>	5.77 $\pm$ 0.18 <sup>a</sup>	5.75 $\pm$ 0.18 <sup>a</sup>
PLT $\times 10^9/l$	237.35 $\pm$ 24.64 <sup>ab</sup>	212.75 $\pm$ 16.07 <sup>a</sup>	266.34 $\pm$ 16.57 <sup>ab</sup>	283 $\pm$ 13.36 <sup>b</sup>

a, b and c: There is no significant difference ( $P > 0.05$ ) between any two means for the same attribute, within the same row have the same superscript letter.

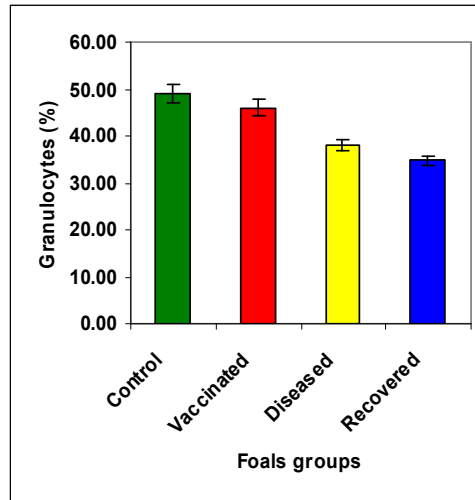
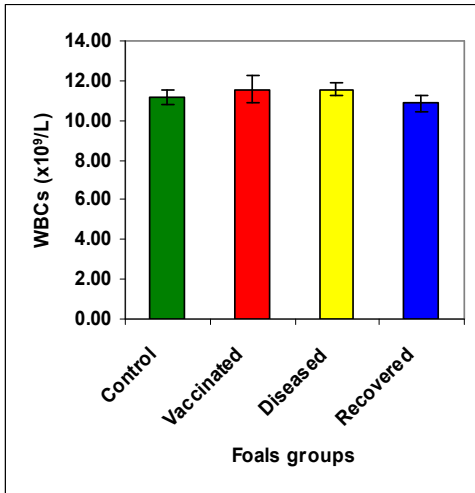


Figure (8): Changes in total leukocyte count. Figure (9): Changes in Granulocytes count.

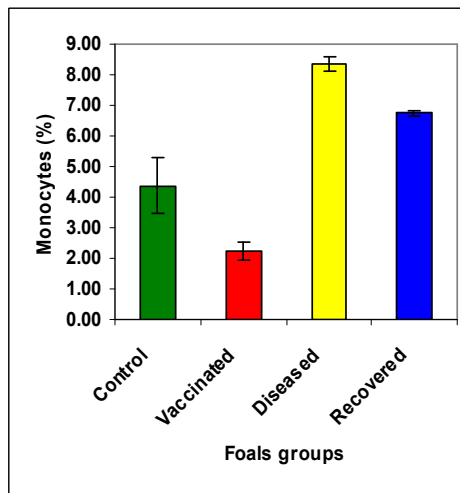
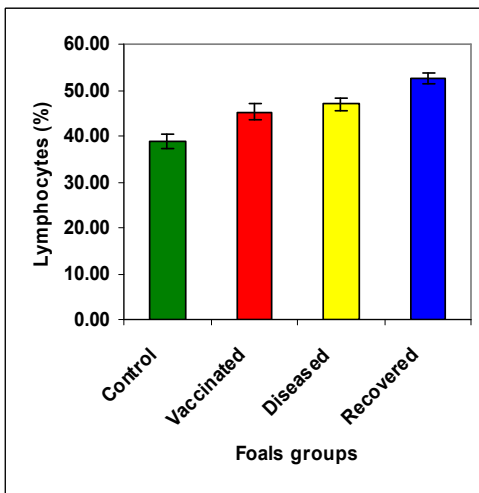


Figure (10): Changes in lymphocytes count. Figure (11): Changes in monocyte count.

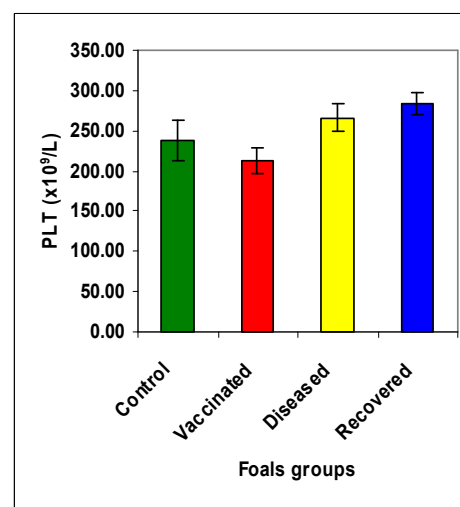
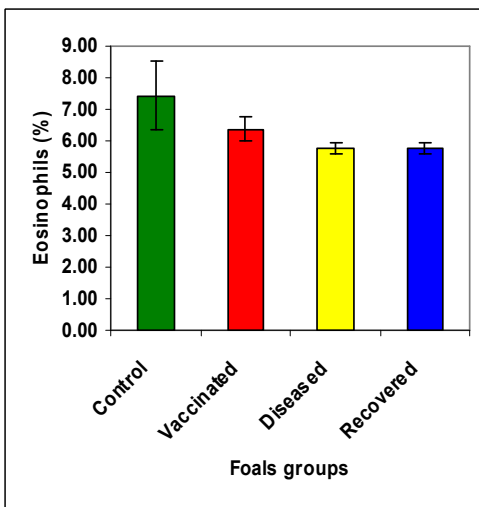


Figure (12): Changes in eosinophil count. Figure (13): Changes in Platelet count.

**2. Biochemical profiles:**

The results (table 3, Fig. 14-17) showed that there were significant decreases in serum protein in diseased, recovered, and vaccinated foals groups when compared with control group. Concerning to results of albumin and globulin, there were a significant decrease in diseased and recovered foals groups when compared with control group, while there were non-significant decrease in vaccinated foals group, in comparison with control group. Regarding to A/G ratio, there was a significant increase in diseased and recovered foals groups when compared with control group, while there was non-significant decrease in vaccinated foals group, in comparison with control group.

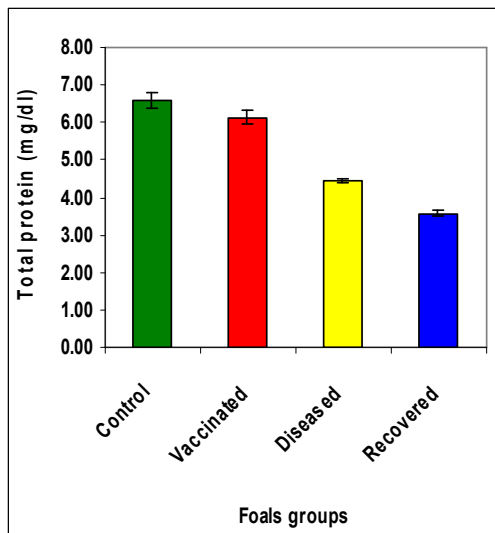
ALP showed a significant decrease in diseased, recovered and vaccinated foals groups when compared with control group. GGT revealed non-significant decrease in diseased foals group, significant decrease in recovered foals group and a significant increase in vaccinated foals group, in comparison with control group.

GOT showed non-significant changes in diseased and recovered foals groups and a significant increase in vaccinated foals group, in comparison with control group.

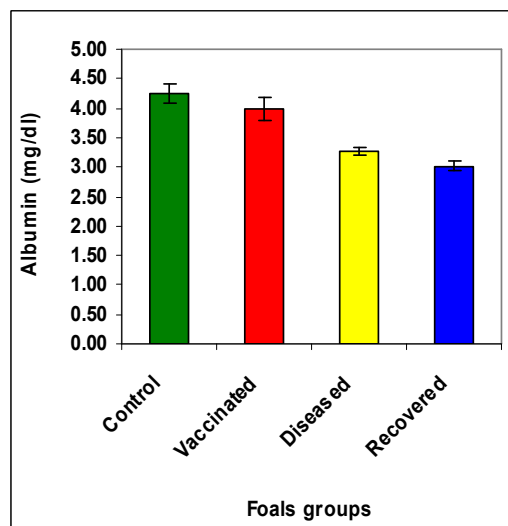
**Table (3): Biochemical profile in foals groups (mean±SE).**

Parameter	Foals Groups			
	Control	Vaccinated	Diseased	Recovered
Total protein g/dl	6.57±0.20 <sup>d</sup>	6.13±0.18 <sup>c</sup>	4.45±0.07 <sup>b</sup>	3.58±0.05 <sup>a</sup>
Albumin g/dl	4.25±0.17 <sup>b</sup>	3.99±0.20 <sup>b</sup>	3.26±0.09 <sup>a</sup>	3.02±0.07 <sup>a</sup>
Globulin g/dl	2.32±0.24 <sup>c</sup>	2.14±0.19 <sup>c</sup>	1.19±0.12 <sup>b</sup>	0.64±0.08 <sup>a</sup>
A/G ratio	2.37±0.46 <sup>a</sup>	2.03±0.28 <sup>a</sup>	4.03±0.75 <sup>b</sup>	7.06±1.26 <sup>c</sup>
ALP (U/L)	864.40±37.97 <sup>b</sup>	587.88±54.09 <sup>a</sup>	622.88±32.11 <sup>a</sup>	564.04±33.75 <sup>a</sup>
GGT (U/L)	6.80±0.90 <sup>b</sup>	9.00±1.39 <sup>c</sup>	5.88±0.57 <sup>ab</sup>	4.24±0.44 <sup>a</sup>
GOT (U/L)	221.87±4.85 <sup>a</sup>	240.00±5.77 <sup>b</sup>	210.77±4.98 <sup>a</sup>	219.84±4.81 <sup>a</sup>

a, b and c: There is no significant difference ( $P > 0.05$ ) between any two means for the same attribute, within the same row have the same superscript letter.



**Figure (14): Changes in total protein.**



**Figure (15): Changes in albumin.**

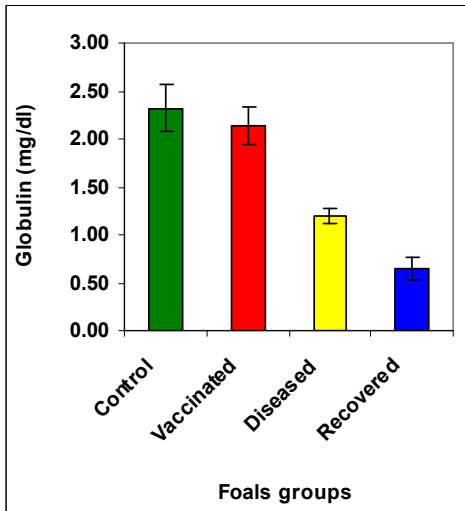


Figure (16): Changes in globulin.

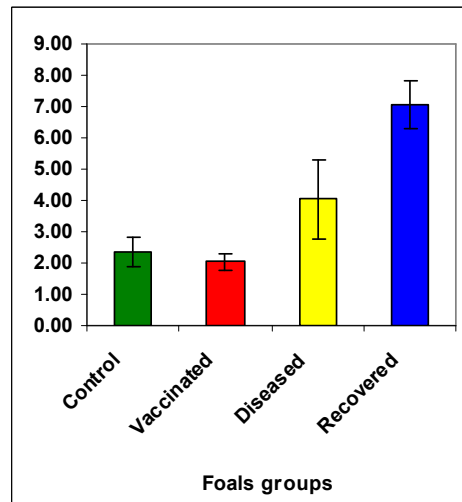


Figure (17): Changes in A/G ratio.

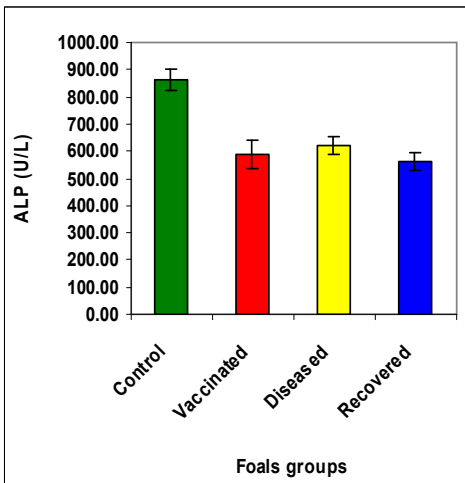


Figure (18): Changes in ALP.

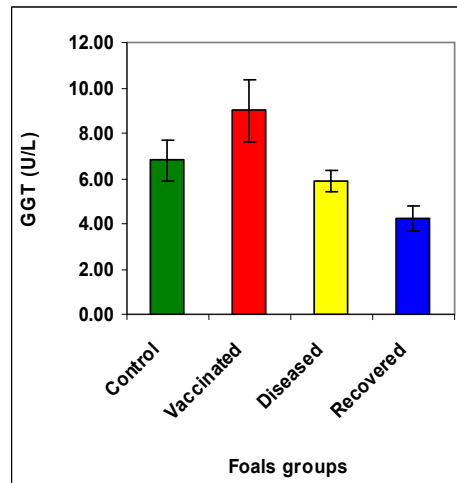


Figure (19): Changes in GGT.

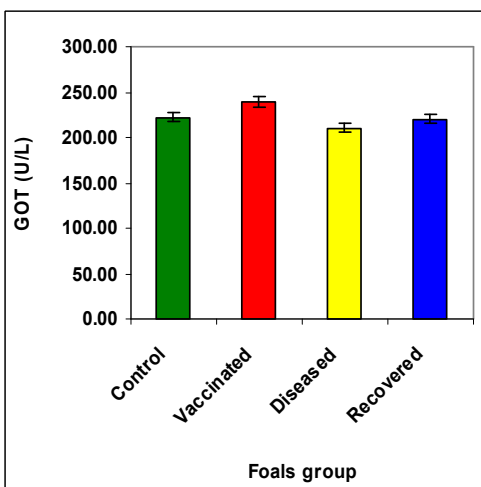
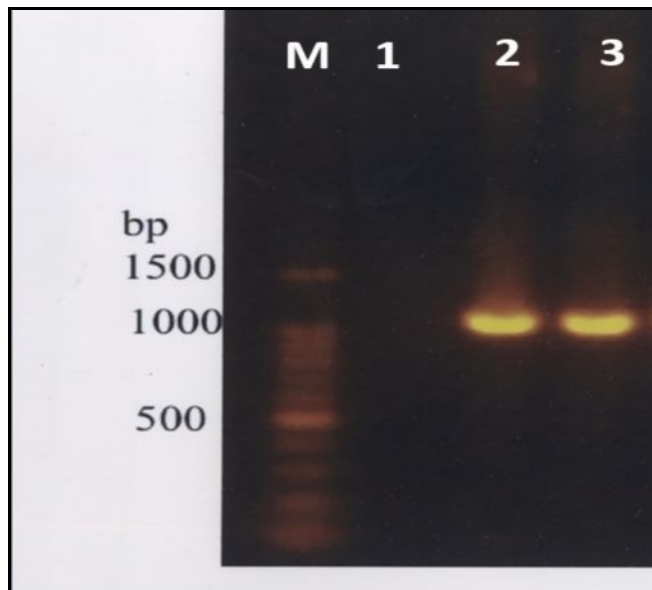


Figure (20): Changes in GOT.



### 3. Result of PCR

Gel electrophoresis (Fig.21) of semi-nested PCR product of DNA amplification from nasal swab of diseased foals group and the positive and negative control.



**Fig.21: Gel analysis of PCR product for EHV-1.**

Lane 1: PCR product of the negative control, Lane 2: PCR product of the positive control, Lane 3: PCR product of the sample from nasal swab.

### Discussion

Polymerase chain reaction can be used for rapid amplification and diagnostic detection of the nucleic acid of EHV-1 and EHV-4 present in respiratory tract swab or lavage samples or blood (fresh or frozen) or fixed tissue samples<sup>12</sup>. However, the sensitivity of PCR tests in clinical samples is reduced, probably from the presence of inhibitors of the polymerase enzyme, other impurities within the DNA, and degradation of the viral DNA target<sup>2</sup>. In this study, Semi-nested PCR showed PCR product of amplification from nasal swab (infected foal group and positive control as well as no PCR product for the negative control (control group). The previous results were supported by<sup>13,14</sup>. Data of erythrogram parameters (RBCs count, PCV, and Hb values) showed a significant decrease in diseased and recovered foals groups and non-significant decrease in vaccinated foals group than that of control group. These results were in agreement with<sup>15</sup> who reported mild anaemia with equine herpes virus infection.

Spherocytosis was observed in blood film smear in diseased and recovered foals groups. Presence of erythrocyte spherocytosis with anemia reflect the pathogenesis of immune hemolytic anemia involves production of antibodies to red cells resulting by lysis and erythrophagocytosis<sup>16,17</sup>. These abnormal rigid cells may be removed by the splenic reticulo-endothelial cells or may be lyse in circulation due to increased osmotic fragility<sup>18</sup>. In addition, positive serological titer for infectious cause, absence of evidence of other immune hemolytic anemia (Toxicosis, drug associated or microangiopathic), erythrocyte autoagglutination and ghost erythrocytes in the blood film and monocytosis in leukogram were other laboratory or diagnostic features of IHA cases<sup>1,17</sup>. In our study mild immune mediated hemolytic anemia was reported in foals as a secondary to infection. The present results agreed with<sup>16</sup> who mentioned that an immune hemolytic anemia uncommon in adult horse.

MCHC values increased significantly in diseased and recovered foals groups. Spherocytosis, which noted in our results effect on MCHC results by increasing it. Spherocytic process cause loss of cell volume in excess of Hgb; generally, however, spherocytes only appear to be hyperchromic because of their thickness, and their MCHC values are increased<sup>17</sup>. The total leukocytic count showed non-significant change in diseased and

recovered foals groups if compared with the control group. Our results were in agreement with those obtained by <sup>19</sup> who reported that the totals of WBCs showed non-significant changes in foals with respiratory infections.

In this study, decrease of granulocytes was observed in diseased and recovered foals. <sup>20</sup> explained that neutropenia was observed after intranasal inoculation foals with EHV-1. Neutropenia results when margination in vessels or emigration of neutrophils to inflamed tissue exceeds the release of neutrophils from marrow <sup>17, 21,22</sup> supported our result; they recorded depression in neutrophils counts in the herpes positive foals.

The lymphocytes showed a significant increase in diseased, recovered and vaccinated foals groups when compared with control group. Lymphocytosis in this study may be physiological which associated with excitement or exercise and commonly occurs in horse under two years of age as well as foals in our study is yearling <sup>1</sup>. On the other hand, lymphocytosis may be due to antigenic stimulation by viral infection which recorded in the infected and recovered foals groups or by vaccination which recorded in vaccinated foals group <sup>16, 23</sup> supported our result and reported that inflammatory lower airway disease (LAD) increased proportions of inflammatory cells and LAD was statistically associated with tracheal infection with EHV-1 and EHV-4. Our results were in coincidence with <sup>24</sup> who found that vaccinated horses showed a marked increase in the cell-mediated immune response to equine herpesvirus 1.

The monocytes showed a significant increase in diseased and recovered foals groups and a significant decrease in vaccinated foals group, in comparison with control foals group. Monocytosis occurred due to acute inflammation caused by equine herpes infection by cytokine stimulation of monocyte production and release, generally monocytosis reflects a need for macrophages in diseased tissue or blood <sup>17</sup>. Our results were in agreement with those obtained by <sup>25, 26</sup> observed that after 24 hours since inoculation of EHV-1 there was a slight rise of temperature and the laboratory tests showed leukocytosis which was maintained for several days) with increase of monocytes in blood.

Eosinopenia showed in diseased and recovered foals groups. Acute inflammation is the main cause of eosinopenia <sup>17</sup>. In our study, infected and recovered foals showed eosinopenia due to acute inflammation by EHV infection.

There wasn't elevation in liver enzyme values (ALP, GOT, GGT) in diseased and recovered foal groups, while GOT and GGT revealed significant increase in vaccinated foals group only. <sup>21</sup> explained that no significant difference in liver enzyme values (ALP, GGT, and GOT) in EHV-1 positive neonatal foals and these were in agreement with our results.

Albumin revealed significant decrease in diseased and recovered foals groups when compared with control group. Albumin is negative APP, which decrease during APP <sup>26</sup>. Fever in foals during respiratory sings can increase metabolic demands which cause excessive albumin breakdown during negative nitrogen balance <sup>1</sup>. When the rate of protein catabolism exceeds protein production, the negative protein status results in a hypoproteinemia, before a clinical hypoproteinemia develops, the animal attempts to maintain glucose and most serum proteins (especially albumin) at the expense of other tissues. This hypoproteinemia is expected when there has loss of body weight due to fat and muscle mass (Cachectic states), major laboratory are findings in this states hypoproteinemia, hypoalbuminemia and hypoglobulinemia <sup>17</sup>. Protein was decreased in diseased, vaccinated and recovered foals may be as a result of feverish and malnutrition. In general, the component of serum protein changes as a result of decreased albumin and globulin.

In conclusion, present work reported clinicopathological changes associated with of EHV-1 infection in Arabian foals.

## References

1. Brown, C.M. and Bertone, J.J. 2002: The 5-Minute Veterinary Consult- Equine', Lippincott, Williamsand Wilkins.
2. Slater, J.D. 2007: Equine herpesvirus in Equine infectious disease. Section II. Saunders-Elsevier publisher, Philadelphia, pp. 134-153.
3. Allen, G.P. and Bryans, J.T. 1986: Molecular epizootiology, pathogenesis and prophylaxis of equine herpesvirus 1 infections. *Progr. Vet. Microbiol. Immunol.* , 2: 78-144.

4. Studdert, M.J., Hartley, C.A., Dynon, K., Sandy, J.R., Slocombe, R.F., Charles, J.A., Milne, M.E., Clarke, A.F. and El-Hage, C. 2003: Outbreak of equine herpes virus type 1 myeloencephalitis: new insights from virus identification by PCR and the application of an EHV-1-specific antibody detection ELISA. *Vet. Record* 153: 417–423.
5. Giles, R.C., Donahue, J.M., Hong, C.B., et al. 1993: Causes of abortion, stillbirth, and perinatal death in horses: 3,527 cases, *J Am Vet Med Assoc*; 203(8): 1170-1175.
6. Murray, M.J., Del Piero, F., Jeffrey, S.C., Davis, M.S., Furr, M.O., Dubovi, E.J. and Mayo, A. 1998: Neonatal equine herpesvirus type 1 infection on a thoroughbred breeding farm. *Journal of Veterinary Internal Medicine*; 12: 36–41.
7. Pusterla, N., Wilson, W.D., Mapes, S., Finno, C., Isbell, D., Arthur, R.M. and Ferraro, G.L. (2008): Characterization of viral loads, strain and state of equine herpesvirus-1 using real-time PCR in horses following natural exposure at a racetrack in California. *Veterinary Journal*. doi:10.1016/j.tvjl.2007.09.018, Epub ahead of print.
8. Perkins, G.A., Goodman, L.B., Dubovi, E.J., Kim, S.G. and Osterrieder, N. (2008): Detection of equine herpesvirus-1 in nasal swabs of horses by quantitative real-time PCR. *Journal of Veterinary Internal Medicine*, 22: 1234–1238.
9. Telford, E.A.R., Watson, M.S., McBride, K. and Davison, A.J. (1992): The DNA sequence of equine herpesvirus-1. *Virology*; 189: 304-316.
10. Hassanein, M.M., Maysa, H., El-Bagoury, F., Magda A.K., El-Kabbany, M.M.A. and Daoud, M.A. (2002): Trails for isolation and identification of equine herpesvirus abortion in Egypt. *Vet. Med. J. Giza*, 50 (4): 977-986.
11. OIE (2008): Equine Rhinopneumonitis. *Manual of standards diagnostic tests and vaccines 5<sup>TH</sup> edition*, chapter 2-2-9 pp 893-903.
12. Allen, G.P., Kydd, J.H., Slater, J.D. and Smith, K.C. 2004: Equid herpesvirus-1 (EHV-1) and -4 (EHV-4) infections. In *Infectious Diseases of Livestock*, (Ed.) JAW Coetzer and RC Tustin. Oxford Press (Cape Town), Chapter 76, pp 829-859.
13. Carvalho, R., Oliveira, A.M., Souza, A.M., Passos, L.M.F. and Martins, A.S. 2000: Prevalence of equine herpesvirus type 1 latency detected by polymerase chain reaction. *Arch. Virol.*, 145: 1773–1787.
14. Amer, H.M., Shaltout A.K., El-Sabagh, I.M., El-Sanousi, A.A. and Shalaby, M.A. 2011: Prevalence of equine herpes viruses 1, 2 and 4 in Arabian horse population in Egypt. *African Journal of Microbiology Research* 5(27): 4805-4811.
15. Pusterla, N., Wilson, W.D., Madigan, J.E. and Ferraro, G.L. 2009: Equine herpesvirus-1 myeloencephalopathy: A review of recent developments. *The Veterinary Journal*; 180: 279–289.
16. Morris, D.D. Diseases of the Hemolymphatic System. In: Colahan, P.T., Mayhew, I.G., Merritt, A.M. and Moore, J.N. 1991: *Equine Medicine and surgery*, 4th edition, Volume 2, Goleta. American Veterinary Publications, Goleta, pp.1753–1859.
17. Stockham, S.L. and Scott, M.A. 2002: *Fundamentals of Veterinary Clinical Pathology*. 1st edition, Black Well Publishing Company, Iowa State Press.
18. Jain, N.C. 1986: *Schalms Veterinary Haematology*. 4th ed. Lea and Febiger, Philadelphia. pp 990-1039.
19. Al Azab, A.A. 2011: *Clinicopathological Studies on Some Respiratory Affection in Horses*. A thesis for master degree, Faculty of Veterinary Medicine, Zagazig University.
20. Gibson, J.S., Slater, J.D., Awan, A.R. and Field, H.J. 1992: Pathogenesis of equine herpesvirus-1 in specific pathogen- free foals: primary and secondary infections and reactivation. *Archives of Virology*, 123: 351–366.
21. Perkins, G., Ainsworth, D.M., Erb, H.N., Del Piero, F., Miller, M., Wilkins, P.A., Palmer, J. and Frazer, M. 1999: Clinical, haematological and biochemical findings in foals with neonatal Equine herpesvirus-1 infection compared with septic and premature foals. *Equine Vet J.*, 31(5):422-426.
22. Hultén, C. and Demmers, S. 2002: Serum amyloid A (SAA) as an aid in the management of infectious disease in the foal: Comparison with total leucocyte count, neutrophil count and fibrinogen. *Equine Veterinary Journal*; 34(7):693-698.
23. Wood, J.L.N., Newton, J.R., Chanter, N. and Mumford, J.A. 2005: Association between Respiratory Disease and Bacterial and Viral Infections in British Racehorses. *Journal of Clinical Microbiology*; 120–126.
24. Kydd, J.H., Watrang, E. and Hannant, D. 2003: Pre-infection frequencies of equine herpesvirus-1 specific, cytotoxic T lymphocytes correlate with protection against abortion following experimental infection of pregnant mares. *Vet Immunol Immunopathol*; 96(3-4): 207-17.

25. Mason, D.K., Watkins, K.L., McNie, J.T. and Luk, C.M. 1990: Haematological measurements as an aid to early diagnosis and prognosis of respiratory viral infections in thoroughbred horses. *Vet Rec.* 126(15):359-63.
26. Lucian, I., Carmen, I., Braticevici, F.C., Simona, I., Andrei, T., Aneta, P. and Alexandru, T. 2010: Research on variation of haematological parameters, blood chemistry and protein fractions in horses with respiratory disease, after taking a herbal extract. *Romanian Biotechnological Letters.* University of Bucharest; 15 (3): 5267-5273.

\*\*\*\*\*