

Screening of Leaf Extracts of *Holoptelea Integrifolia*(Roxb.) Planch for it's Antiarthritic activity In Experimental Animals

Ravindra C. Sutar^{1*}, Sanjay B. Kasture¹ and V.K. Kalaichelvan²

¹Department of Pharmacology, Sanjivani College of Pharmaceutical Education and Research, Kopergaon. At-Sahajanandnagar, Post-Shinganapur (Pin code- 423603), Tal- Kopergaon, Dist-Ahmednagar, Maharashtra, India.

²Department of Pharmacy, Annamalai University, Annamalai Nagar, Chidambaram (Pin code- 608002), Tamil Nadu, India.

*Corres.author: ravi_sutar1980@yahoo.com, Mobile: 09028337225.

Abstract: The main objective of the work was to evaluate the traditional claim of *Holoptelea Integrifolia* (HI) leaves for it's antiarthritic activity by using petroleum ether (PEHI) and methanolic (MHI) extract of *Holoptelea Integrifolia* (HI) leaves in complete Freund's adjuvant (CFA) model. The antiarthritic activity of different doses of HI extract (100 and 300 mg/kg) in rats were evaluated on 7th, 14th and 21st day of treatment. The paw volume displacement, radiographic analysis, and secondary lesions changes were measured, as a mark of antiarthritic activity. The HI extracts at the dose of 100 and 300 mg/kg showed significant reduction in paw volume on 7th, 14th and 21st day of treatment and also significant effect in radiographic analysis. Petroleum ether extract was more significant than methanol extract and showed dose dependent effect. Petroleum ether extract was more potent than methanol extract for showing antiarthritic activity. The results indicate that petroleum ether and methanol extracts contained phyosterols and flavonoids which may be active in case of complete Freund's adjuvant induced arthritis which confirms the ethnomedicinal application of the plant as an antiarthritic agent.

Keywords: Antiarthritic, complete Freund's adjuvant, *Holoptelea Integrifolia* leaves

Introduction

Rheumatoid arthritis (RA), one of the commonest autoimmune diseases, is a chronic, progressive, systemic inflammatory disorder affecting the synovial joints and typically producing symmetrical arthritis that leads to joint destruction, which further may be responsible for the deformity and disability especially in a substantial socio-economic impact and hence need to be addressed at all times [1,2]. Overall it involves a complicated pathogenesis, with pathological changes in multiple targets [3]. Literature data of arthritis in female: male is 3:1 affecting about 1% population in developed countries. Many steroidal, non-steroidal, immunosuppressive and disease modifying antirheumatic drugs (DMARD's) are used to prevent and treat the sign and symptoms of inflammation. Complete Freund's adjuvant (CFA) induced arthritis is an experimental model which considered closest to simulating human rheumatoid arthritis. The appearance of secondary lesions (uninjected paw swelling) are the manifestation of cell mediated immunity (T cell response particularly CD4+ T cells). In traditional system of medicine, bark and leaves of *Holoptelea Integrifolia* (HI) used as bitter, astringent, acrid, thermogenic, anti inflammatory, digestive, carminative, laxative, anthelmintic, depurative, repulsive, urinary astringent and in rheumatism [4,5]. The plant *Holoptelea integrifolia* is used traditionally for the treatment of inflammation, gastritis, dyspepsia, colic, intestinal worms, vomiting, wound healing, leprosy, diabetes, hemorrhoids, dysmenorrhoea and rheumatism [6]. But, its antiarthritic activity is not yet validated scientifically as on date. Hence in the current dissertation the antiarthritic activity of petroleum ether and methanol extract of leaf of *Holoptelea Integrifolia* in experimental animals is evaluated.

Materials and Methods

Plant Material:

Leaves of *Holoptelea Integrifolia* were collected in the Month of August from the agricultural fields of Tirunelveli district, Tamilnadu. The plant was identified and leaves of *Holoptelea Integrifolia* were authenticated and confirmed from Dr.V.Chelladurai, Research Officer, Botany, C.C.R.A.S. (Retired), Govt. of India by comparing morphological features (leaf and stem arrangement, flower /inflorescence arrangement, fruit and seed morphology etc.). The collected plant material was shade dried to retain its vital phytoconstituents and then subjected to size reduction for further extraction process.

Chemicals and Drugs: Complete Freund's adjuvant (CFA), *Methotrexate*. Complete Freund's adjuvant (CFA) was purchased from Sigma Aldrich and Methotrexate was obtained from the market. All the solvents used for the extraction were of AR grade.

Preparation Of Different Extracts: Successive extraction of leaves of *Holoptelea Integrifolia* was done on the basis of solvent polarity

Preparation of Petroleum ether (PEHI) and methanol (MHI) extract: The powder of *Holoptelea Integrifolia* leaves was charged in to the thimble of a Soxhlet apparatus and extracted using petroleum ether. Appearance of colourless solvent in the siphon tube was the indication of exhaustive extraction and based on that the further extraction was terminated. The extract was then transferred into the previously weighed empty beaker and evaporated to a thick paste on the water bath, maintained at 50° C to get petroleum ether extract. The extract was finally air dried thoroughly to remove all traces of the solvent and the percentage yield was calculated. The perfectly dried extract was then stored in an air tight container in a refrigerator below 10°C. After obtaining the petroleum ether extract the marc was pressed and it is air dried and again it was extracted using methanol. Appearance of colourless solvent in the siphon tube was the indication of exhaustive extraction and based on that the further extraction was terminated. The extract was then transferred into the previously weighed empty beaker and evaporated to a thick paste on the water bath, maintained at 50° C to get semi solid mass of methanol extract. The extract was stored in an airtight container in a refrigerator below 10°C.

Storage of Extracts:

Petroleum ether and methanolic extract of HI was stored in tightly closed glass bottles in refrigerator at 2-8°C.

Preparation of Extract Solutions:

Test solutions (T.S) of petroleum ether and methanolic extract of HI was prepared in distilled water in order to make concentration 100 mg/ml.

Animals:

Albino mice of either sex weighing between 20-30 g And albino rats of either sex weighing between (180-220) gm were procured from Central Animal House, Rajah Muthiah Medical College & Hospital, Faculty of Medicine, Annamalai University, Annamalai Nagar- 608002,

Tamilnadu, India. for experimental purpose. The animals were acclimatized to laboratory conditions for 7 days. The animals were supplied with commercially available standard diet. They were maintained at 25 ± 2° C and relative humidity of 45 to 55% and under standard environmental conditions (12 hour. light 12 hour. dark cycle). Water was allowed ad libitum under hygienic conditions. All animal studies were performed in accordance to guideline of CPCSEA and Institutional Animal Ethical Committee (IAEC) of Central Animal House, Rajah Muthiah Medical College & Hospital, Annamalai University, Tamilnadu, India.(CPCSEA registration number- 160/1999 /IAEC/CPCSEA, Proposal no:1029). All experiments were carried out between 12:00- 16:00 h.

Preparation of Drug Solution: Accurately weighed quantity of powdered extract of HI was dissolved in the distilled water to prepare the appropriate stock solution of the drug i.e. 10 mg/ml and 30 mg/ml respectively. The doses were administered orally by selecting the appropriate concentration (10 ml/kg) of the stock solution.

Route of Administration: Both petroleum ether and methanolic extract of HI were administered by oral route. CFA was administered by sub plantar route. Methotrexate was administered by oral route.

Acute Toxicity Study:

Healthy adult male wistar albino mice (18- 22g) were subjected to acute toxicity studies as per guidelines (OECD-425) suggested by the organization for economic co-operation and development [7] The mice were administered with the different doses of petroleum ether and methanolic extract of HI or distilled water (10ml/kg). The dose progression or reduction was carried out as suggested by the OECD-425 guidelines.

Statistical Analysis: The comparison was made against the vehicle treated control group and the data was expressed as mean \pm SEM. The data was analysed using suitable test with respect to individual models mentioned later.

Methods:

The different doses (100, 300 mg/kg) of the Petroleum ether and Methanol extracts of *Holoptelea Integrifolia* leaves were subjected to the following investigations,

1. Preliminary phytochemical screening.
2. Pharmacological activities
 - a. Determination of acute toxicity (LD₅₀)
 - b. Antiarthritic Activity

Evaluation of Antiarthritic Activity using Freund's Complete Adjuvant Model:

Thirty six preselected male rats (having mean displacement value without any significant difference) were divided in six groups each consisting of 06 rats. All rats were made arthritic by single intra-dermal injection of 0.1 ml of Complete Freund's adjuvant (CFA) containing 1.0 mg dry heat-killed *Mycobacterium tuberculosis* per milliliter sterile paraffin oil into a foot pad of the left hind paw of rats and immediately after this following treatment was started for the period of next 21 days.

- Gr 1- Vehicle- 10ml/kg-po
- Gr 2- PEHI- 100 mg/kg-po
- Gr 3- PEHI- 300 mg/kg-po
- Gr 4- MHI- 100 mg/kg-po
- Gr 5- MHI- 300 mg/kg-po
- Gr 6- Methotrexate- 0.75 mg/kg-po

60 minutes after dosing, the left hind paw volumes of displacement using digital plethysmometer and appearance as well as severity of secondary lesions were measured on 1st, 7th, 14th and 21st day (8,9) . The results of secondary lesions are given in table no.2. Thereafter Radiographic analysis was carried as a supportive parameters using procedure mentioned below.

Radiographic analysis.

On the 21st day immediately after measurement of paw volume displacement and recording of secondary lesions, one rat from each group was sacrificed by cervical dislocation and subjected to the radiological examination using Agfa digital System and Seimens X ray machine. These radiographs were evaluated for any deformity especially for soft tissue swelling and bone erosion, joint space narrowing by independent qualified person (8) .

Results

Evaluation of Antiarthritic Activity using Freund's Complete Adjuvant Model (Paw Volume Displacement In MI):

The paw volume of rats of all groups recorded on the 0th day was found to be similar. The intra group did not show any significant change due to selection of similar weight and age range animals. The paw volume displacements of control group, rats pretreated with PEHI extract 100 and 300 mg/kg and *Methotrexate*

(0.75mg/kg) rats on the 7th day after CFA injection were found to be 1.91 ± 0.050 , 1.77 ± 0.021 , 1.60 ± 0.030 and 1.29 ± 0.014 respectively. Control rats and MHI extract 100 mg/kg treated rats showed significant inflammation. The PEHI extract 100 mg/kg, 300 mg/kg and *Methotrexate* treated rats also showed significant reduction in inflammation. The PEHI 300 mg/kg and *Methotrexate* (0.75mg/kg) were equipotent ($P < 0.01$) and more significant than PEHI 100 mg/kg treatment ($P < 0.05$). On 21st day, evaluation showed significant reduction in the inflammation with PEHI 100 and 300 mg/kg treatment as compared with vehicle treated rats. Here PEHI 100 mg/kg was less significant ($P < 0.05$) than the other higher dose and *Methotrexate* treatment ($P < 0.01$). Amongst both these doses the PEHI-300 is more significant than MHI- 300 mg/kg. The results are given in table no. 1

Table 1: Effect of petroleum ether and methanol extracts of *Holoptelea Integrifolia* (Roxb.) Planch leaves on Paw volume displacement (ml).

Gr No.	Treatment	Paw displacement volume (ml)			
		1 st day	7 th day	14 th day	21 st day
1	Vehicle- 10ml/kg	1.18 ± 0.020	1.91 ± 0.050	1.78 ± 0.034	1.78 ± 0.029
2	PEHI- 100 mg/kg	1.19 ± 0.018	1.77 ± 0.021*	1.59 ± 0.035**	1.66 ± 0.022*
3	PEHI- 300 mg/kg	1.23 ± 0.013	1.60 ± 0.030**	1.49 ± 0.040**	1.48 ± 0.043**
4	MHI- 100 mg/kg	1.20 ± 0.018	1.83 ± 0.041	1.75 ± 0.031	1.76 ± 0.020
5	MHI- 300 mg/kg	1.20 ± 0.015	1.76 ± 0.024*	1.63 ± 0.022*	1.73 ± 0.028
6	<i>Methotrexate</i> 0.75 mg/kg	1.23 ± 0.015	1.29 ± 0.014**	1.25 ± 0.019**	1.26 ± 0.017**

Values are mean ± SEM; n=6; Statistical Analysis- one way ANOVA followed by Dunnetts 't' test

* $P < 0.05$, ** $P < 0.01$, *** $P < 0.001$, PEHI: Petroleum ether extract of *Holoptelea Integrifolia* leaves, MHI: methanol extract of *Holoptelea Integrifolia* leaves

Table 2: Effect of petroleum ether and methanol extracts of *Holoptelea Integrifolia* (Roxb.) Planch leaves on secondary lesions.

Gr No.	Treatment	Secondary lesions			
		1 st day	7 th day	14 th day	21 st day
1	Vehicle- 10ml/kg	---	+	++	+++
2	PEHI- 100 mg/kg	---	+	++	+
3	PEHI- 300 mg/kg	---	+	+	+
4	MHI- 100 mg/kg	---	---	+++	++
5	MHI- 300 mg/kg	---	---	++	++
6	<i>Methotrexate</i> 0.75 mg/kg	---	---	---	---

Nil: --- ; Mild :+; Moderate :++; Severe:+++.

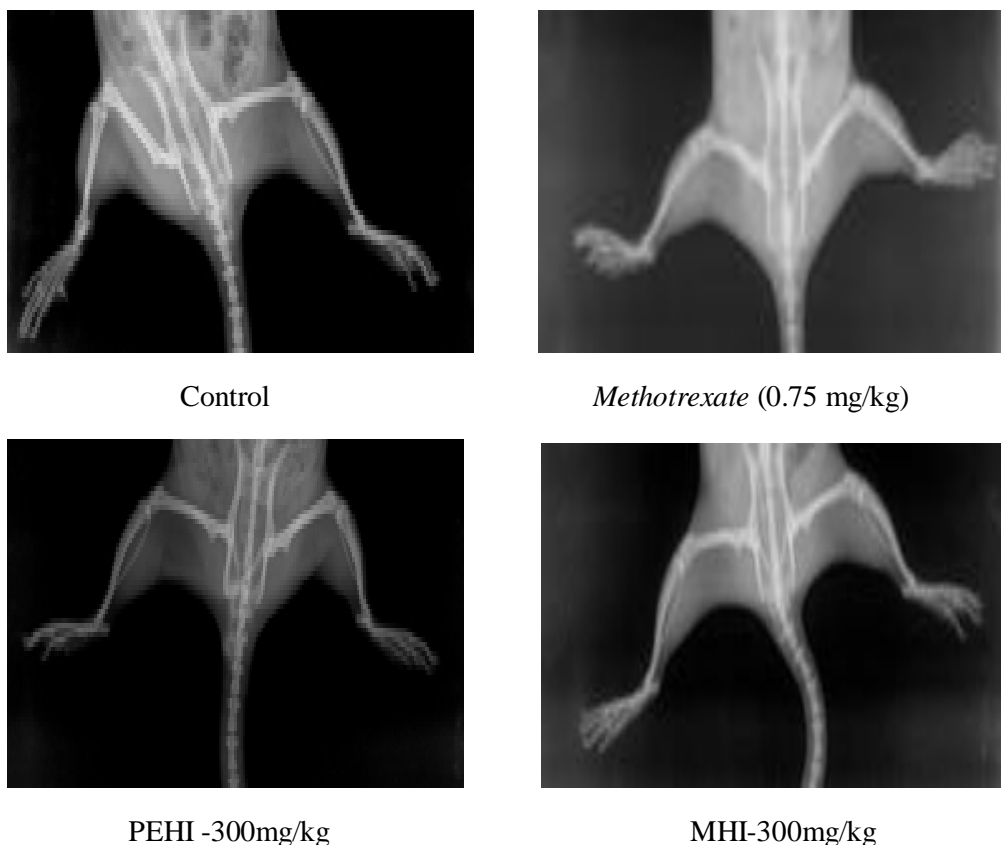
PEHI: Petroleum ether extract of *Holoptelea Integrifolia* leaves, MHI: methanol extract of *Holoptelea Integrifolia* leaves

Note: Secondary lesions on the 21st day were collectively observed in the ear, fore-paws, hind-paws and tail of rats (9).

Radiographic Analysis:

As shown in figure 1, radiographic examination of CFA injected hind paws of control rat exhibited uneven narrowing of the joint spaces, and subsequent bone cartilage destruction in the knee joint and significant soft tissue swelling indicating full blown arthritis. Whereas, PEHI extracts 100 mg/kg and 300 mg/kg treated rat showed remarkable reduction in soft tissue swelling as well as destruction of the knee joints. Moreover, the joint space is more even as compared against the vehicle treated control rats. Similar but more potent results were seen in rats treated with *Methotrexate*.

Fig 1: Effect of petroleum ether and methanol extracts of *Holoptelea Integrifolia* (Roxb.) Planch leaves on the proximal interphalangeal joints of control and experimental rats



Discussion:

Pharmacotherapy using plant-derived substances can be currently regarded as a very promising future alternative to current synthetic drug therapy. The advanced techniques and technologies available today enable to investigate chemically well-defined bioactive plant components as sources of novel drugs [10] to evaluate the toxicity profile so as to confirm safety of petroleum ether and methanolic extract of *Holoptelea Integrifolia* prior subjected to any preclinical pharmacological screening the acute toxicity study was carried out. Our findings indicated that the extract was found to be devoid of any toxic symptoms and no mortality was found up to 2000 mg/kg [7] from this report two different doses i.e 100 and 300 mg/kg of petroleum ether and methanol extracts were selected for further study. *Holoptelea Integrifolia* has been recognised in different systems of traditional medicines for the treatment of various different diseases and ailments of human beings. We have scientifically explored some of its important claims and possible uses. It has been traditionally claimed to be useful in joint rheumatism. Literature survey of the plant has already been reported for its significant antiinflammatory effect which suggest it's possible use in various joint pain treatment approaches. The current literature survey also revealed that no systematic approach has been made towards documentation of this claim. On the contrary, Rheumatoid arthritis (RA), one of the commonest autoimmune diseases prominently manifested by the joint pain and inflammation has reported a large number of mortality and morbidity and thereby left substantial socioeconomic impact [2] The currently available large number of synthetic drugs, especially steroidal drugs are mainly used for symptomatic relief and also associated with numerous side effects. These limitations in turn demand for alternative value added therapy. With these difficulties, the field of

arthritis research has become a prominent thrust area [3] Modern research in the field of anti-arthritic therapy is directed towards developing potent compounds with wide acceptability, non-toxicity and the ability to suppress the immune response to an antigen. In light of this, the anti-arthritic activity of *Holoptelea Integrifolia* using Complete Freund's Adjuvant induced arthritis model was performed. The present investigation reported that the higher dose of the petroleum ether extract showed improvement in arthritis condition by reducing hind paw inflammation and secondary lesions than the methanol extract. The improvement in secondary lesions is the hallmark of anti-arthritic activity of the extract. These results postulated possible dual role of petroleum ether extract as a symptomatic therapy and preventive remedy which can be considered as a value added outcome as compared to modern therapy. An ideal therapy in rheumatoid arthritis is expected in halting of the disease pathology rather than pure symptomatic relief. Radiographic analysis is considered to be the best tool to screen any drug in this regard. In this study, radiographic analysis of the joint showed significant prevention in the progress of joint pathology which is perhaps the most desired effect in Rheumatoid arthritis. In this model of arthritis, complex composition of bacterial adjuvant leads to initiation of a multistage process of immune response. Hence, the test drug is effective i.e HI petroleum ether extract indicates immunosuppressant potential [11, 12]. In synthetic medication, rapid reduction in inflammation in Rheumatoid arthritis is observed with corticosteroids however they are effective for a short term. Corticosteroid become less effective over time and rheumatoid arthritis is usually active for year's together. The above observed optimal immunosuppressant action coupled with significant anti-inflammatory activity of the petroleum ether extract suggests that it can be a good substitute to the current corticosteroid therapy. In rheumatoid arthritis pain, inflammation and immune response are the key parameters that ultimately govern the disease pathology. In this way, the use of the petroleum ether extract as a long term therapy in treatment rheumatoid arthritis is the most important outcome of this study.

Conclusion

The petroleum ether extract of *holoptelea integrifolia* leaves is more potent for showing the antiarthritic activity than the methanol extract. The extracts showed dose dependent effect. Since phytosterols like beta-sitosterol have been found useful in treatment of rheumatoid arthritis [13,14,15] due to their anti-inflammatory and immunomodulatory functions we have concentrated on isolation and identification of a new phytosterol for showing the observed antiarthritic activity, also our study confirms the traditional claim for the use of *holoptelea-integrifolia* leaves in the treatment of Rheumatoid Arthritis disorders as a need of modern health science.

References

1. Smolen J S, Steiner G. Therapeutic strategies for rheumatoid arthritis, *Nat Rev Drug Discov*, 2 (2003) 473–88.
2. Buch M, Emery P. The aetiology and pathogenesis of rheumatoid arthritis. *Hospital Pharmacist*, 2002; 9: 5–10.
3. Gabriel SE. The epidemiology of rheumatoid arthritis. *Rheumatic Disease Clinics of North America* 2001; 27: 269–282.
4. Kirtikar K R, Basu B D. *Indian Medicinal Plants*. 3rd edition. Sri Satguru Publications, New Delhi, India .2000; Vol-III: 2292-2294.
5. Prajapati, N D., S S Purohit and A K Sharma. *A Handbook of Medicinal Plants a Complete Source Book*. Agrobias. Jodhpur. India. 2003; 273.
6. Warriar P K., Nambiar V P K. , Ramakutty C. *Indian Medicinal Plants a compendium of 500 species*, Orient longman private Limited. 1995; 3: 162.
7. OECD Guideline For The Testing of Chemicals: Guidance document on acute oral toxicity. *Environmental Health and Safety Monograph Series on Testing and Assessment* 2000.
8. Wilder R L, Calandra G B, Garvin A J, Wright K D, Hansen CT. Strain and sex variation in the susceptibility to streptococcal cell wall-induced polyarthritis in the rat. *Arthritis and Rheumatism* 1982; 25 (9):1064–1072.
9. Newbould B B. Chemotherapy of Arthritis induced in rats by Mycobacterial adjuvant. *Brit J Pharmacol* 1963; 21: 127-136.
10. Philipson JD. Phytochemistry and pharamacognosy. *Phytochemistry* 2007; 68:2960–72.
11. Crofford LJ, Wilder RL. Arthritis and autoimmunity in animals. In: Mccarty, D.J., Koopman, W.J. (Eds.), *Arthritis and Allied Conditions*. Lea and Febiger, London, 1993; 525–539.

12. Walz DT, Di Martimo MJ, Misher A. Adjuvant-induced arthritis in rats. II: drug effects of physiologic, biochemical and immunologic parameters. *Journal of Pharmacology* 1971; 178: 223–231.
13. Bouic, PJD. Sterols/Sterolins: The natural, nontoxic immuno-modulators and their role in the control of rheumatoid arthritis. *The Arthritis Trust* 1998; Summer:3-6.
14. Gupta MB, Nath R, Srivastava N. Anti-inflammatory and antipyretic activities of β -sitosterol. *Planta Medica* 1980;39:157-163.
15. Bouic PJD, Etsebeth S, Liebenberg RW, et al. Beta-sitosterol and beta-sitosterol glycoside stimulate human peripheral blood lymphocyte proliferation: implications for their use as an immunomodulatory vitamin combination. *Int J Immunopharmacol*1996:18:693-700.
